

CONTINUING EDUCATION for Physical Therapists

DISTAL RADIUS FRACTURES: REHABILITATIVE EVALUATION AND TREATMENT

PDH Academy Course #PT-1903 | 5 CE HOURS

Course Abstract

This course addresses the rehabilitation of patients with distal radius fractures. It begins with a review of relevant terminology and anatomy, next speaks to medical intervention, and then examines the role of therapy as it pertains to evaluation, rehabilitation, and handling complications. It concludes with case studies.

NOTE: Links provided within the course material are for informational purposes only. No endorsement of processes or products is intended or implied.

Approvals

To view the states that approve and accept our courses, visit <https://pdhtherapy.com/physical-therapy/>

Target Audience & Prerequisites

PT, PTA, OT, OTA – no prerequisites

Learning Objectives

By the end of this course, learners will:

- Differentiate between definitions and terminology pertaining to distal radius fractures
- Recall the normal anatomy and kinesiology of the wrist
- Identify elements of medical diagnosis and treatment of distal radius fractures
- Recognize roles of therapy as it pertains to the evaluation and rehabilitation of distal radius fractures
- Distinguish between potential complications resulting from distal radius fractures

Timed Topic Outline

- I. Introduction; Definitions, Terminology, and Provocative Testing (30 minutes)
- II. Normal Wrist Anatomy and Kinesiology (20 minutes)
Bones of the Wrist; Ligaments of the Wrist; Normal Movement Patterns of the Wrist
- III. Wrist Fractures (10 minutes)
Classifications; Mechanisms of Injury; Occurrence/Epidemiology
- IV. Overview of Medical Intervention (15 minutes)
Non-Operative Treatment/Casting/Immobilization; Surgical Treatment of Fractures
- V. Rehabilitation/Healing Timeline (180 minutes)
Evaluation for Rehabilitation; Treatment; Complications
- VI. Case Studies; Conclusion (20 minutes)
- VII. Additional Resources, References, and Exam (25 minutes)

Delivery Method

Correspondence/internet self-study, with a provider-graded multiple choice final exam. *To earn continuing education credit for this course, you must achieve a passing score of 80% on the final exam.*

Cancellation

In the unlikely event that a self-study course is temporarily unavailable, already-enrolled participants will be notified by email. A notification will also be posted on the relevant pages of our website. Customers who cancel orders within five business days of the order date receive a full refund. Cancellations can be made by phone at (888) 564-9098 or email at support@pdhacademy.com.

Accessibility and/or Special Needs Concerns?

Contact Customer Service by phone at (888)564-9098 or email at support@pdhacademy.com.

Course Author Bio & Disclosure

Amy L. Paulson, OTR, CHT, is a certified hand therapist with over 19 years of experience in outpatient upper extremity care. She has been a licensed occupational therapist for 20 years, has experience in home health, skilled nursing, and acute care, and is a member of the American Society of Hand Therapists.

Amy has led multiple community-based classes on arthritis care, energy conservation and work simplification, and she taught as an adjunct professor at Palm Beach Community College in the OTA program. She designs and instructs hands-on continuing education courses in splinting and upper extremity treatment, and enjoys providing clinical instruction to students interested in specializing in hand therapy. She is also involved in coordinating and overseeing therapy programs in Gulu, Uganda by volunteering with the Medical Missions Foundation of Overland Park, KS, and is co-founder of the Gulu Project, a non-profit organization that is building an outpatient village for the burn patients of Northern Uganda.

Amy currently owns and operates her private practice in outpatient hands, where she provides patient care, clinical instruction to Level II students, community education, marketing, and insurance billing.

DISCLOSURES: Financial – Amy Paulson received a stipend as the author of this course. Nonfinancial – No relevant nonfinancial relationship exists.

Introduction

A recent (2015) Cochrane Database Systematic Review of 26 randomized controlled studies of patients with simple distal radius fractures (DRF) was summarized with the following statement: “The available evidence from RCTs (Randomized Control Trials) is insufficient to establish the relative effectiveness of the various interventions used in the rehabilitation of adults with fractures of the distal radius.” In other words, patients don’t get any better with treatment than they do with a list of home exercises given by their physician.

At first glance, this can put a therapist (like myself) on the defensive, as we believe that what we do is not only important, but vital to full functional use of the hand.

Fortunately, as one dives deeper into the review, we find that it admits to not studying patients with “serious fracture or treatment-related complications, or older people with co-morbidities and poor overall function that would have precluded trial participation or required more intensive treatment.” Ah, there’s the difference. Patients with simple wrist fractures and no comorbidities don’t need extensive hand therapy. I agree with that.

But how many of our patients present with one simple injury and no significant medical history? Our patients are complicated. They have chronic illness, old conditions, scheduling issues, and family drama. This course is designed and dedicated to addressing all the nuances of treating those patients that do require our services – patients who aren’t one dimensional and who will have limited use and chronic pain if we don’t intervene. We will discuss the current research, the evidence behind why we do what we do, and most importantly, how to do it. We have plenty of skilled treatment to render. Let’s get to work.

PLEASE NOTE: it is not within the scope of occupational therapy to prescribe. The information presented in this course is not intended nor is it

implied to be a substitute for professional medical advice.

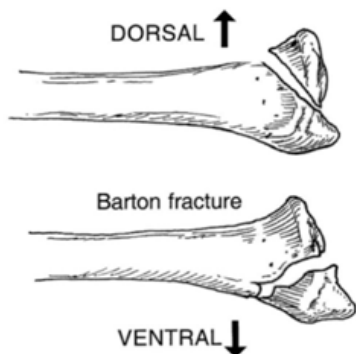
Amy's note: My primary goal for any readers of this course is to keep up with the latest research while learning practical information that they can use immediately in a clinic setting. In addition, occasionally I will toss in more personal musings, indicated by italicized writing. Text in italicized print is based in large part on my opinions, generated by 22 years of practical experience as a hand therapist – not solely science and research. This is what I like to call “evidence-based practice with a side dish of clinical experience (or old age)”. For as we all know, and Albert Einstein so aptly stated, “In theory, theory and practice are the same. In practice, they are not.”

I. Definitions, Terminology, and Provocative Testing

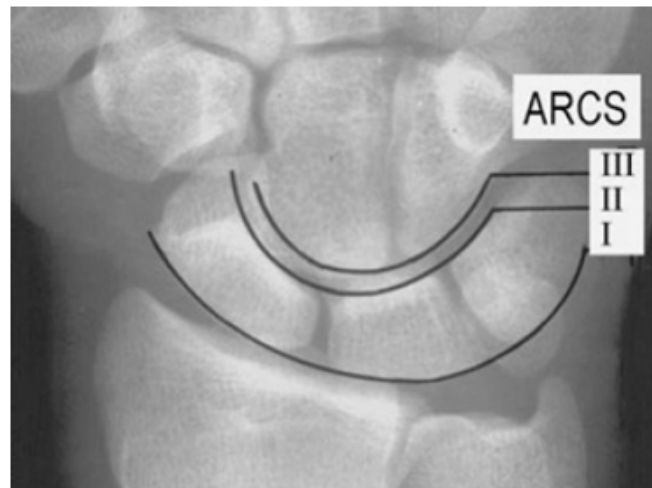
Definitions

Avascular necrosis: Death of bone tissue due to lack of blood supply to the tissue. If blood flow is cut off from a section of fractured bone, the fragment is at risk to die.

Barton fracture: An intra-articular fracture of the distal radius similar to a Colles fracture in that it displaces dorsally, but different from Colles in that it does not extend to both the dorsal and volar aspects of the radial articular surface, but rather one or the other. This fracture usually involves dislocation of the radio-ulnar joint as well. Typically fixated with a volar locking plate.



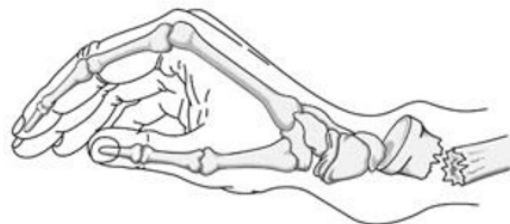Carpal arcs: There are three carpal arcs noted on normal x-rays. The first is the proximal edge of the proximal row (scaphoid, lunate, triquetrum), the second arc is the distal edge of these same three bones, and the third arc is the proximal edge of the middle portion of the distal row (capitate and hamate). Disruptions of these carpal arcs suggest ligamentous disruption or bony dislocation or fracture.



Chauffer fracture: Intra-articular fractures of the radial styloid process. These occur most commonly from a blow to the dorsal wrist. Typically reduced with closed reduction and percutaneous pinning or a lag screw.

Closed fracture: Any fracture that does not puncture the skin. These may or may not require surgery depending on the degree of displacement or comminution.

Colles fracture: A transverse, extra-articular fracture of the distal radius (distal 2cm of the radius) that is angulated dorsally and impacted by the proximal carpal row (the scaphoid and lunate), caused by a fall on an outstretched hand. Colles fractures occur proximal to the distal radioulnar joint. Colles fractures are the most common type of distal radius fractures and occur most often in young children and the elderly.



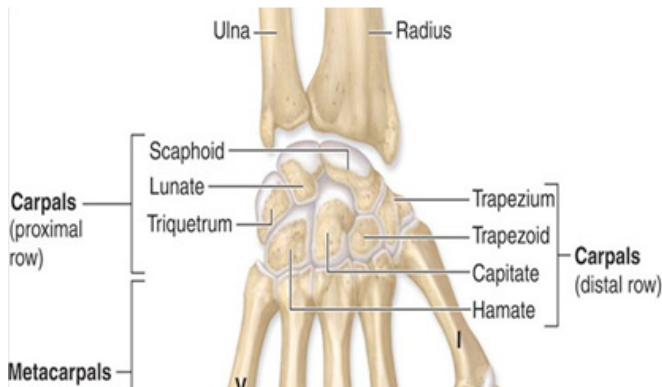
Comminuted fracture: Any fracture that results in many bone fragments, such as those that can occur with a crush injury or high-velocity fall.

Complex Regional Pain Syndrome (CRPS): Formerly known as Reflex Sympathetic Dystrophy (RSD), this is a complication that can occur after distal radius fracture where the brain has a loss of pain inhibitory mechanisms and a hyperactivation of ascending pain pathways which results in excruciating pain, changes in sleep patterns, increased swelling, stiffness, and loss of function to the hand. CRPS can occur due to any injury, but is often seen after DRF and will greatly impact function.

Displaced fracture: A fracture that results in movement of the bony fragment away from its proper alignment.

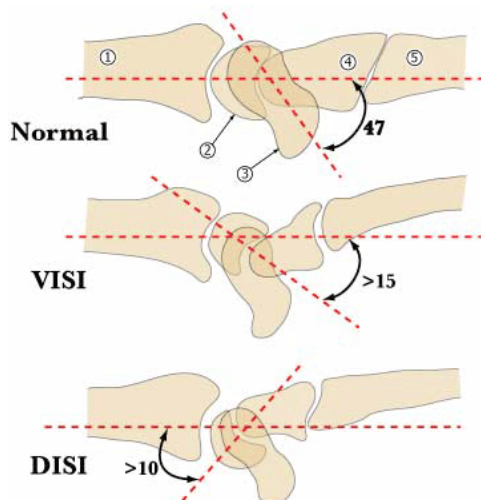
Technically any fracture that is displaced more than 2mm in any plane on x-ray is considered displaced. Displaced fractures can be manually or surgically reduced depending on the severity.

Distal carpal row: The carpal bones that make up the distal row are the trapezoid, capitate, and hamate. These bones articulate with the proximal carpal row and the metacarpals.



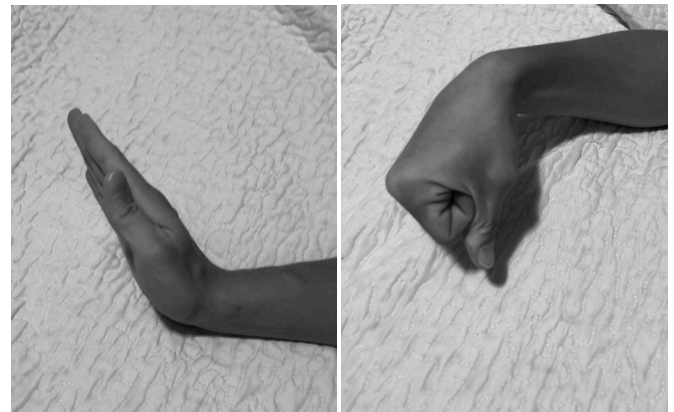
Distal radioulnar joint (DRUJ): The articulating surface between the radius and the ulna at the distal end of the forearm. The ulnar notch is the articulating surface located at the end of the radius, and this travels around the distal end of the ulna with pronation and supination. This works in conjunction with the PRUJ to provide forearm motion.

Dorsal intercalated segmental instability (DISI): Also known as dorsiflexion instability; abnormal dorsal tilt of the lunate (and volar tilt of the scaphoid) due to the disruption of the scapholunate (SL) ligament. This is more common than VISI mid-carpal instability. A normal SL angle is 30-60 degrees, and the SL angle of someone with DISI is greater than 70 degrees. A DISI should be suspected if normal carpal arch is noted to be disrupted on a posterior/anterior view x-ray. This injury can be confirmed on a natural lateral view x-ray.



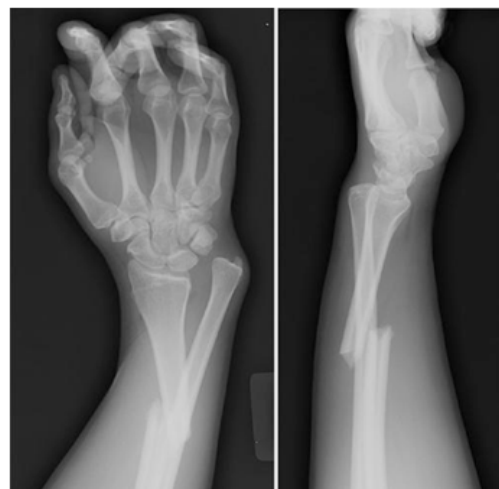Extra-articular fracture: This refers to a fracture that does not extend into the articular surface of the radius. One of the most important descriptors of a fracture, extra-articular fractures tend to be less complicated and have better functional outcomes than intra-articular fractures unless they are comminuted.

Extrinsic tightness: Soft tissue restrictions to the finger flexors or extensors. This includes the flexor digitorum superficialis (FDS) and flexor digitorum profundus (FDP) muscles and the extensor digitorum communis (EDC). This is common to see with distal radius fractures and can be tested by placing the patient in full extension (simultaneous wrist and finger extension) to assess for extrinsic flexor tightness, or full flexion (simultaneous wrist flexion with a fist) to assess for extrinsic extensor tightness. If a patient loses finger motion with manipulation of the wrist, there is extrinsic tightness.

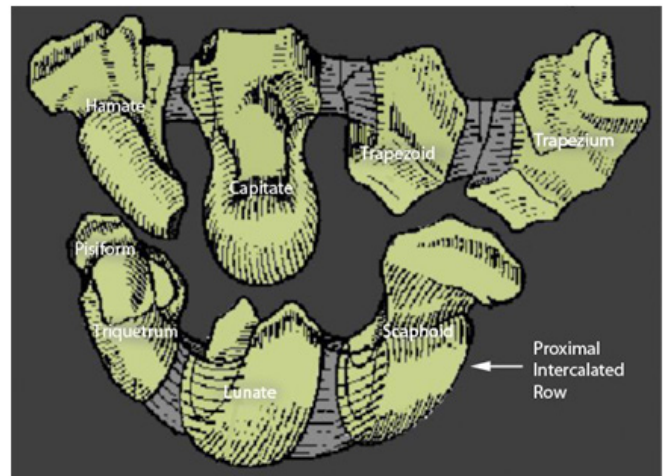
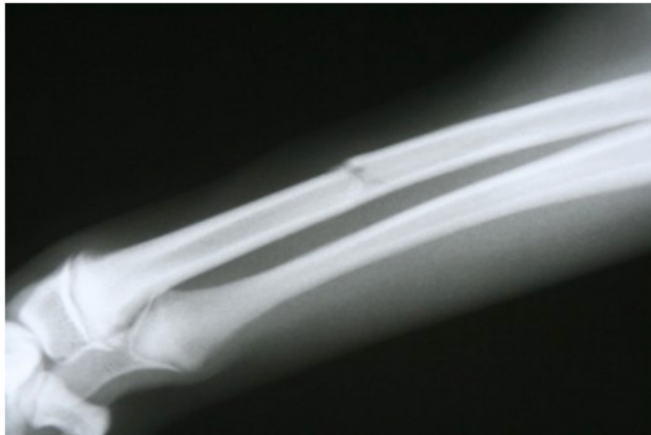

FOOSH: acronym for a “fall on an outstretched hand,” often the precipitating factor in distal radius fractures. Most patients fall forward on a pronated forearm, trying to catch themselves to break the fall resulting in a dorsal displacement of the fractured piece.

Galeazzi fracture: Unstable fracture of the radial shaft with DRUJ disruption. These have a high risk of malunion and are almost always treated with an Open Reduction Internal Fixation (ORIF) in adults due to propensity for chronic dislocation of the ulna. These fractures also commonly have radial nerve involvement.

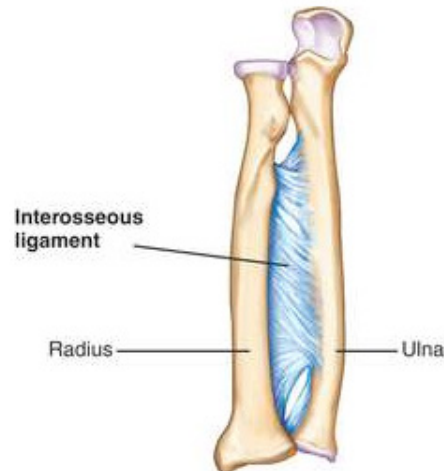
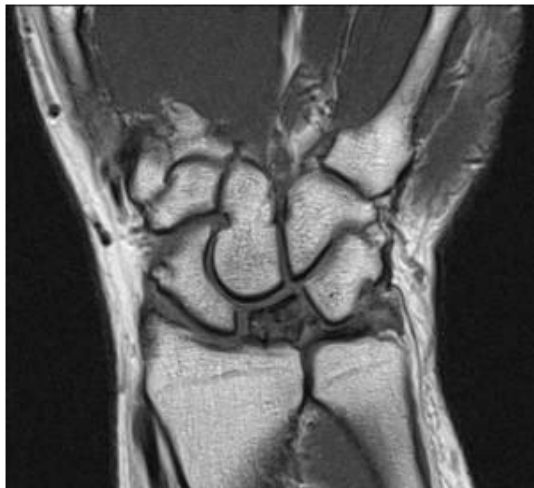

Greenstick fracture: Named in reference to how a young “green” tree branch will bend and break on the outside when you attempt to snap it, this describes a fracture where the bone bends and breaks as opposed to breaking in two separate pieces. Commonly seen in children younger than ten years old, they typically heal completely in 3-5 weeks and do not require therapy.



Interosseous membrane: A large fibrous membrane traveling between the radius and ulna extending the length both bones. This membrane provides stability in the forearm and also serves to compartmentalize the volar and dorsal portions of the forearm.

Kienbock’s disease: Avascular necrosis of the lunate, usually caused by negative ulnar variance following a wrist fracture. The negative ulnar variance causes the radius to exert undue stress on the lunate because of the change in joint dynamics at the DRUJ.



Intra-articular fracture: This refers to a fracture that extends to the articular surface of the bone, causing damage to the cartilage and potentially the ligament attachments as well. These types of injuries may result in degenerative arthritis. Colles, Smiths, and Chauffeur fractures are the most commonly seen intra-articular fractures in the distal forearm. They involve the radiocarpal joint, the distal radioulnar joint, or both.

Intercalated row concept: The carpal bones that make up each row are each bound together by very short ligaments, making them an intercalated segment. They do not have direct individual control with movement, but work together as a row. These bones move in direct response to the muscular force regulated by the ligaments that connect the forearm and the distal carpal row.

Intrinsic tightness: Tightness due to adhesions or muscle spasm and shortening to the intrinsic muscles of the hand, particularly the lumbrical muscles. If the patient has intrinsic tightness, the PIP joint will have more passive motion with the MP flexed than it will with the MP extended. This is described in more detail under the Bunnel-Littler test for intrinsic tightness.

Minimum clinically important difference (MCID): This is the smallest change or difference in an outcome measure that is perceived to be important by the patient.

Minimal detectable change (MDC): This is the minimum change score that must be observed before a clinician can be confident that a change in patient status (due to intervention) has occurred rather than measurement error. This can be measured at all different percentages. (In other words, HOW CONFIDENT is the clinician that the change occurred? For example, an MDC95 means the clinician is 95% certain the change is not due to measurement error.)

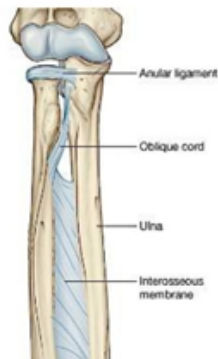Non-displaced fracture: A full or partial fracture of the bone that does not move away from its proper alignment. Non-displaced fractures are typically treated with conservative casting or splinting to allow time for healing.

Open fracture: Any fracture that punctures the skin. These fractures must be fixed with surgery.

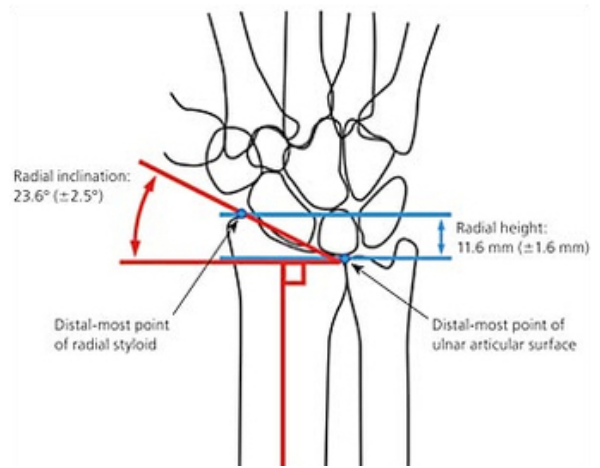
Proximal carpal row: The carpal bones that make up the proximal row are the scaphoid, lunate, and triquetrum. These three bones articulate with the forearm bones (radius and ulna) proximally and the distal carpal row distally. (See image under “distal carpal row”)

Proximal radioulnar joint (PRUJ): The articulating surface between the radius and the ulna at the proximal end of the forearm. The radial head rotates longitudinally around the ulna for forearm pronation and supination. This works in conjunction with the DRUJ to provide forearm motion.

- **Type: Uniaxial pivot joint.**
- **Articulating surfaces**
 - Circumference of the radial head
 - Fibro-osseous ring formed by ulnar radial notch & annular ligament



Radial inclination: This is a measurement that is taken on x-ray in the posteroanterior (PA) view. One line runs along the long axis of the radius, and the tangent line is drawn from the radial styloid to the ulnar corner of the lunate fossa (across the distal surface of the radius in the PA view). This angle is normally between 15-25 degrees. An angle of less than this can suggest an impaction fracture of the distal radius. This information can be used to help identify a fracture (when taken at the time of an injury) or can help the physician determine if he obtained a good reduction of a fracture (during surgery).

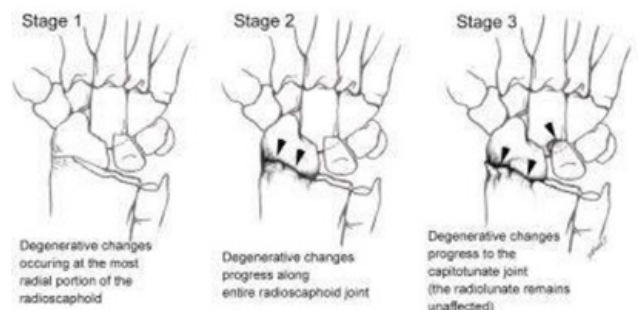


Radial length: Also referred to as radial height, this measurement is taken on x-ray in the posteroanterior (PA) view. One line runs along the long axis of the radius, and then two perpendicular tangential lines are drawn at the distal tip of the radial styloid and the distal articular surface of the ulnar head. The difference in space between these two perpendicular lines is the radial length (or height). A normal measurement is 10-13mm. (See image above)

Reverse Barton fracture: Also known as a Volar Barton fracture or Type II Smith fracture, this is a volar-displaced fracture of the distal radius that extends into the dorsal articular surface of the radio-carpal joint.

Salter-Harris fracture: Fracture of the growth plate of children or teens. These are serious, as they can affect the child’s growth, and need to be assessed by a hand surgeon.

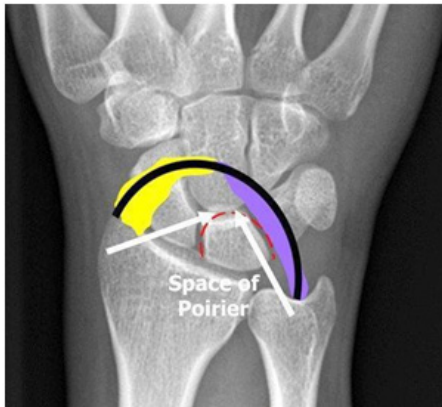
Scapholunate Advanced Collapse (SLAC): Pattern of osteoarthritis and subluxation due to untreated chronic scapholunate dissociation or from chronic scaphoid non-union. Repetitive abnormal loading at the radial-scaphoid joint (as is seen with distal radius fractures) causes breakdown in this area and increased loading (and damage) at the lunatocapitate joint as the capitate subluxes dorsally on the lunate.



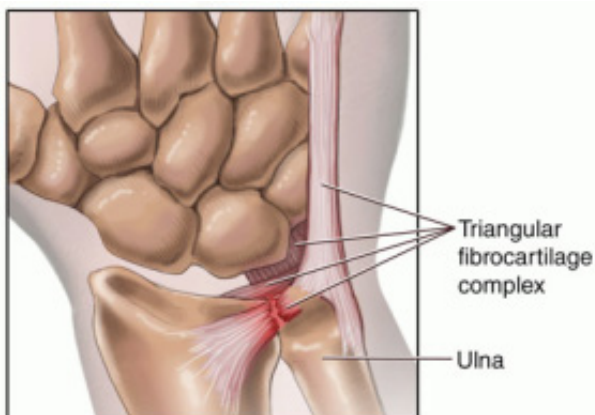
Smith fracture: A transverse, extra-articular fracture of the distal radius that is angulated volarly from falling on a flexed wrist or from a severe blow to the dorsal aspect of the wrist. Also known as a reverse Colles fracture. Occurs

much less commonly than Colles fracture and accounts for only 3% of distal radius fractures (Zhang, 2012).

Space of Poirier: The space in between the proximal and distal carpal rows. This space is analyzed on x-ray and arthrogram when evaluating for carpal instability or fracture lines.



Triangular fibrocartilage complex (TFCC): A soft tissue structure at the end of the ulna that helps stabilize the wrist and transfers some of the load off of the wrist with compression and weight bearing. The TFCC is the primary stabilizer of the distal radioulnar joint. It is made up of three structures: the triangular shaped fibrocartilage disc that is a hammock for the carpal bones, the radio-ulnar ligaments, and the ulnocarpal ligament complex. The TFCC allows almost double the load to be tolerated by the ulna with weight bearing. The TFCC has fairly poor blood supply, so it does not heal conservatively when damaged. Tears to the TFCC commonly occur in conjunction with distal radius fracture or as a result of fracture healing and positive ulnar variance (see ulnar impaction syndrome). Damage to the TFCC can present clinically as ulnar-sided wrist pain and/or “popping” with resisted pronation or supination, and difficulty with full weight bearing over the hand and wrist. Treatment involves immobilization for 4-6 weeks followed by therapy to regain pain-free motion. If conservative treatment is unsuccessful, arthroscopy for debridement and ligament repair may be appropriate.

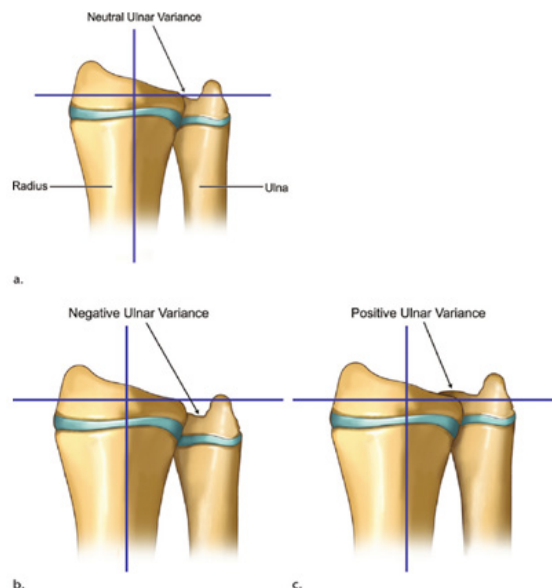


Ulnar impaction syndrome: Also called ulnocarpal abutment syndrome; the ulna has a positive ulnar variance and impinges on the TFCC during pronation, causing irritation and degeneration to the TFCC. Since the cartilage of the TFCC is hypovascular, it will not heal on its own. This causes ulnar sided wrist pain and can result in traumatic arthritis. If left untreated, it will diminish a patient’s grip strength.

Ulnar styloid fracture: Fracture of the ulnar styloid occurs in about 50-60% of cases of Colles fracture and is a negative indicator for outcomes.

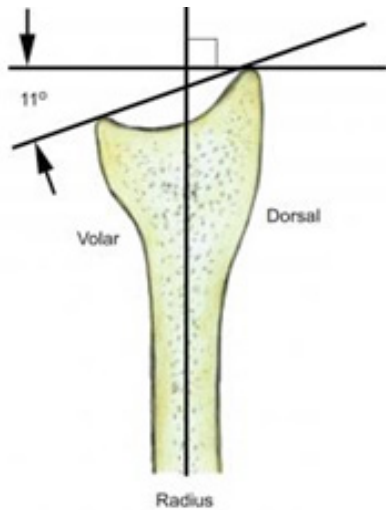
Ulnar translation: With pronation the ulna actually translates slightly in the sigmoid notch of the radius. That is to say, with pronation, the ulna slides distally about 2 mm in relation to the radius. With a fracture of the distal radius, the ability of the ulna to translate may be affected, which can cause pain or stiffness with forearm rotation.

Ulnar variance: In a normal wrist, the distal end of the ulna should be at the same height as the ulnar aspect of the radius. This is considered neutral ulnar variance. In full pronation of the normal wrist, the ulna should translate about 2mm distally on the radius. With full supination, the ulna translates slightly proximally. With injury, this variance can be affected. Negative ulnar variance describes the end of the ulna sitting proximal to the radius, and positive ulnar variance describes the end of the ulna extending beyond the ulnar aspect of the radius. Positive ulnar variance puts the patient at risk for injury to the TFCC, while negative ulnar variance puts the patient at risk for Kienbock’s disease.



Volar intercalated segmental instability (VISI): Also called palmar flexion instability; abnormal volar tilt of the lunate (and dorsal tilt of the capitate), secondary to a disruption of the lunotriquetral ligament. This can also be seen as a normal variant for people with lax ligaments. This injury can be appreciated on a natural lateral view x-ray. (See image under “DISI”)

Volar tilt: Also called volar inclination, this is a measurement that is taken on x-ray in the lateral view. It is the angle between a line drawn perpendicular to the long axis of the radius and the tangential line drawn along the articular surface of the radius running from the dorsal to volar edge of the radius. This angle is normally between 10-25 degrees. A negative volar tilt suggests dorsal angulation of the distal end of the radius and can help identify a fracture (when taken at the time of an injury) or can help the physician determine if he obtained a good reduction of a fracture (during surgery).



Provocative Testing

Berger's test: Test for median nerve compression; the patient is asked to sustain a closed fist for ninety seconds. If the patient complains of numbness or tingling within 90 seconds, the test is marked as positive.



Bunnel-Littler test: This test assesses the hand for intrinsic tightness, or tightness of the intrinsic muscles of the hand (the lumbricals and/or interossei). With the metacarpal phalangeal (MP) joint in slight hyperextension (passively provided by therapist), the therapist passively flexes the proximal interphalangeal (PIP) joint of the finger. Measure the PIP flexion in this position. Now passively flex the MP

joint and PIP joint and measure the PIP joint in this position. If the patient has more PIP motion with the MP flexed than she does with the MP extended, this is intrinsic tightness. (Extrinsic tightness is described above.)




Durkin's test: Test for median nerve compression; the examiner places two thumbs over the pillars of the flexor retinaculum (along the bases of the thenar and hypothenar eminences) and holds pressure over the area. If this causes a tingling or numbing response within 90 seconds, the test is marked as positive.



Grind test: Test to rule out carpometacarpal phalangeal (CMC) joint osteoarthritis; the examiner provides an axial load to the first metacarpal on the trapezium, and performs a circular motion, assessing for joint instability and/or pain. The test is positive if the patient complains of pain or if joint instability or "slippage" is noted.



Phalen's test: Test for median nerve compression; the patient places her hands in a “reverse” praying position, with shoulders abducted, and the dorsal surface of each hand touching. If the patient complains of numbness or tingling within 90 seconds, the test is marked as positive. A reverse Phalen’s test can be administered if the patient is unable to flex the wrists adequately to perform the test. A modified Phalen’s test may be necessary for patients that cannot tolerate this position due to shoulder issues or reduced ROM at the affected wrist. In this case, the examiner can passively flex the patient’s affected wrist to as much flexion as is attainable and maintain that position for 90 seconds. The test is marked positive if numbness and tingling occurs within that time frame.



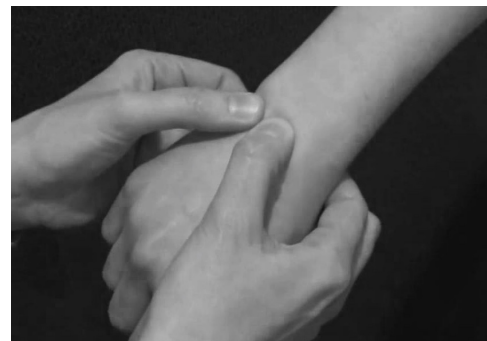Tinel's test: Test for median nerve compression; the examiner taps along the volar forearm from the elbow to the wrist. If this elicits a “tingling” or “zapping” response, the test is marked as positive.



Wrist instability testing:

Wrist instability testing procedures are added here for use if the therapist suspects any ligamentous dysfunction as treatment progresses. These tests should not be used on initial evaluation after a distal radius fracture. They should not be performed until the fracture is fully healed and stable, and the physician has approved strengthening protocol. Tests should be reported as positive or negative. Be very careful not to “diagnose” your patient with any particular wrist instability, but report your findings with positive and negative provocative testing to the physician.

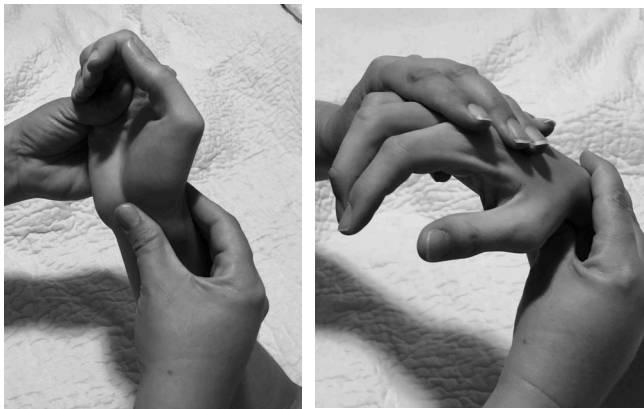
Lunotriquetral ballottement test: Also called a shuck test or shear test, the therapist applies pressure dorsally over the pisiform and palmarly directed pressure over the lunate. (The lunate is just distal and ulnar to the radius.) The alternating pressure creates a shearing stress on the lunotriquetral joint, and is considered positive if the patient complains of pain along with crepitation or a clicking sensation. If the ligament has laxity, this test may have a false negative.



Gripping rotary impaction (GRIT) test: Measures the amount of ulnar impaction present in the wrist. Perform a grip strength test in neutral, pronation, and supinated. The strength ratio of supination to pronation is calculated and compared to the contralateral side. A ration of greater than one is indicative of ulnar impaction (LeStayo, 2001).

Watson's "catch up clunk": Test for rotatory instability of the scaphoid. This test is positive if the Watson's maneuver (as described below) results in a "clunk." This occurs because the lunate remains in a volar flexed and dorsal position until sufficient pressure is applied, and then it catches up with the scaphoid, resulting in a clunking sensation. The test is positive whether or not the patient feels pain with the clunk. This is indicative of scapholunate ligament insufficiency.

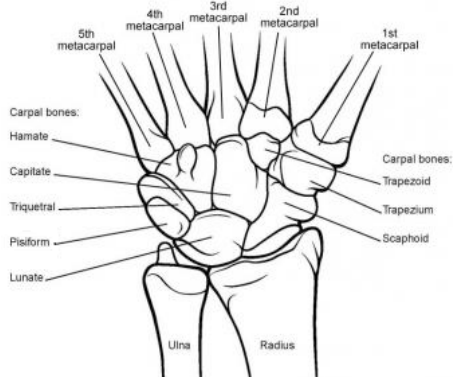
Watson's test: Also known as the scaphoid shift test. This test is done to rule out scapholunate instability. The therapist places four fingers on the dorsal aspect of the radius, and the thumb on the scaphoid tuberosity (volar scaphoid). Position the patient in ulnar deviation and slight wrist extension at the beginning of the test. Passively move the wrist into radial deviation and slight flexion while maintaining thumb pressure of the tubercle of the scaphoid. If the scaphoid is unstable, the proximal pole will be driven dorsally and the patient will complain of pain.



II. Normal Wrist Anatomy and Kinesiology

Bones of the Wrist

Appreciating the complexity of the anatomy of the wrist is important to understanding the nuances of treating a distal radius fracture. The bones that make up the wrist complex are the radius and ulna, the carpal bones, and the base of the metacarpals. The wrist complex is made up of three major articular components: the distal radioulnar joint, the radiocarpal joint, and the mid-carpal joint.

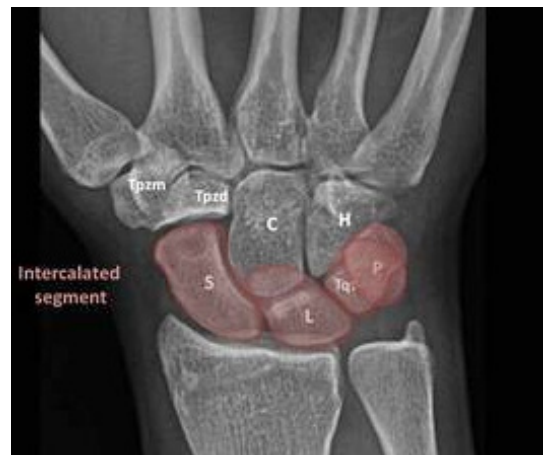

Radius: The distal radius articulates with the scaphoid and the lunate and is called the radiocarpal joint. It actually moves in two directions: flexion/extension, and radial/ulnar deviation. The distal end of the radius tilts volarly around 10-15 degrees. In normal wrist loading (weight bearing), the radius bears 80% of the load coming through the carpal bones. This explains why the radius is most commonly the insulted bone with a fall, as it is taking most of the load. The radius also bears 80% of the load with active gripping, which may affect a patient's functional tolerance after a distal radius fracture.

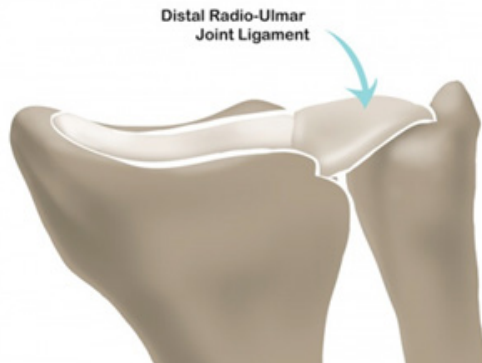Ulna: The ulna does not actually articulate with the carpal bones of the proximal row, but is protected from the weight of the carpal impact by the triangular fibrocartilage complex (TFCC). The ulna bears only 20% of a weight bearing load, and that load is transferred through the TFCC. The ulna slightly translates distally during pronation against the radius, which can cause pain and difficulty after injury.

Carpal Bones: The carpal bones are divided into two distinct rows. The proximal row consists of the scaphoid (S), lunate (L), and triquetrum (Tq) functionally. The pisiform (P) bone has always been considered part of the proximal row, but is actually a sesamoid bone that is the insertion point for the flexor carpi ulnaris tendon. It does not play a role in the functional mobility of the proximal carpal row. The distal carpal row is comprised of the trapezium (Tm), trapezoid (Td), capitate (C), and hamate (H) bones. The metacarpals are numbered 1-5 starting with the thumb. The distal carpal row articulates with the metacarpals, but is not considered part of the functional mobility of the wrist. This is a far cry from the "hinge" that patients think of when they imagine the wrist.

The proximal row is also known as the "intercalated segment," and refers to the scaphoid, lunate and triquetrum as they move in relation to each other with wrist motion. Adding to the complication of the structural continuity, the proximal row has to respond to compressive loads as well (weight bearing). The motion and stability of the proximal row is the primary predictor of pain and poor function when its anatomy is disrupted in any way, which is often the case with a distal radius fracture.



Distal Radioulnar Joint (DRUJ): The distal radioulnar joint is the most proximal joint that comprises the wrist complex. It consists of the head of the ulna, the ulnar notch of the distal radius, and the triangular fibrocartilage complex (TFCC). With movement, the radius rotates longitudinally around the head of the ulna, allowing for pronation and supination of the forearm. The head of the ulna covers 80% of the surface of the DRUJ and articulates with the sigmoid notch of the distal radius and with the inferior surface of the TFCC.



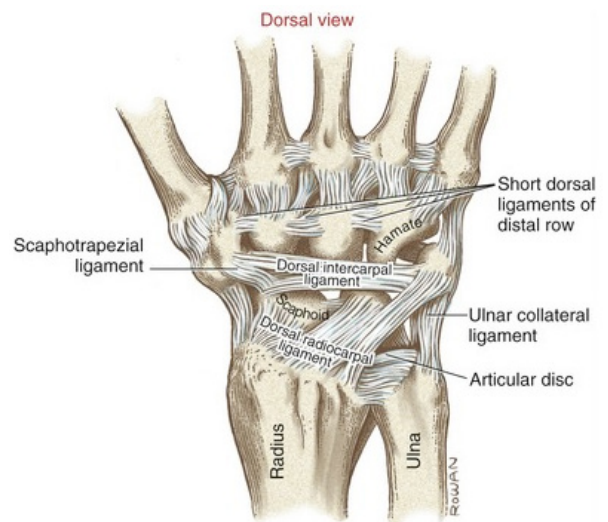
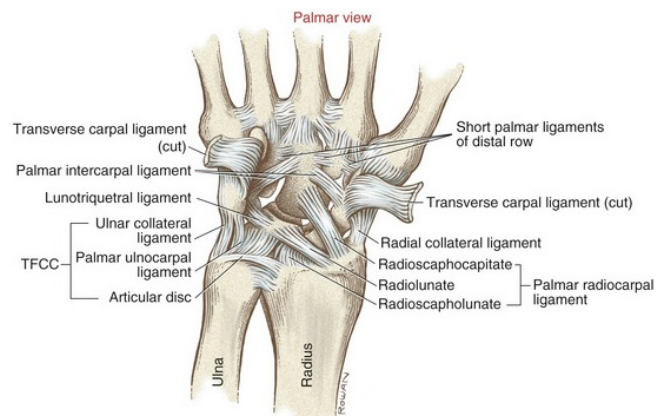
Ligaments of the Wrist

Adding to the bony complexity of the wrist is the ligamentous system holding it all together. The ligaments of the wrist are divided into extrinsic, intrinsic, palmar, and dorsal. Extrinsic ligaments connect the carpals to the surrounding bones (radius, ulna, and metacarpals), and intrinsic ligaments connect each carpal bone to its surrounding carpal bone.

Extrinsic Ligaments: The palmar extrinsic ligaments arise from the ulna and the distal radius, and they connect into both the proximal and distal carpal rows.

All the carpal ligaments are named according to the bones they connect. For example, the radioscaphocapitate ligament (RSC) connects the radius, spans across the distal pole of the scaphoid, and inserts onto the capitate. It is the primary radial stabilizer of the wrist, preventing excessive ulnar translation of the carpal bones over the radius. It actually blends into the ulnocapitate ligament (UC), which provides ulnar-based stability. Two other significant stabilizers of the carpus on the radial aspect of the wrist are the radioscapolunate (RSL) ligament and the long and short radiolunate (LRL, SRL) ligaments with prevent perilunate dislocation. Let's not get confused by all of these names, the therapist should just keep in mind that extrinsic ligaments are the stabilizing force to prevent gross dislocation of the carpus. The palmar extrinsic ligaments are the ulnotriquetral (UT) and ulnolunate (UL) ligaments. They arise from the TFCC and distal ulna, and insert into the triquetrum and lunate respectively. The final extrinsic ligament is the ulnocarpal ligament (UC), which is the most medially based stabilizer between the ulna and the capitate, which blends into the RSC as noted above.

Intrinsic Ligaments: As stated previously, all intrinsic ligaments connect carpal bones to other carpal bones and are named according to the carpals they connect. The intrinsic ligaments are further divided into the palmar and dorsal intrinsic ligaments.



The palmar intrinsic ligaments consist of the scapholunate and lunotriquetral ligaments, as well as the scaphocapitate and triquetrocipitate ligaments. The proximal carpal bones are connected by the scapholunate ligament (SL) on the radial side and the lunotriquetral ligament (LT) on the ulnar side. These two ligaments are responsible for proximal row stability and work to maintain the intercalated segment, meaning the three bones of the proximal row function as a unit with wrist motion. Both the SL and LT ligaments have a palmar, dorsal, and proximal component. The dorsal SL ligament prevents excessive flexion and rotation of the scaphoid, and the volar LT ligament prevents ulnar translation of the lunate. These are the two thickest parts of these ligaments and are the most important to maintain wrist stability for function. The scaphocapitate and triquetrocipitate ligaments connect the proximal and distal rows, and then the trapezio-trapezoid, trapeziocapitate, and capito-hamate ligaments connect the bones of the distal carpal rows. These ligaments play

a much smaller role in functional stability, as these bones tend to act more as a “unit” than the scapoid, lunate, and triquetrum.

The dorsal intrinsic wrist ligaments are less well-defined, and not as strong as the volar intrinsic ligaments. The dorsal radiocarpal (DRC) ligament arises from the distal radius on the radial side of Lister’s tubercle and obliquely inserts onto the triquetrum. It prevents ulnar translation of the carpal bones. The dorsal intercarpal ligaments (DIC) arise from the triquetrum and extend toward the distal pole of the scaphoid and trapezoid. As is noted in the name, the DIC is actually several ligaments that are difficult to differentiate. As a conglomeration, they prevent dorsal dislocation of the capitate from the SL interval.

Not only do the ligaments of the wrist provide stability, but they provide proprioception to the wrist complex as well, which is vital for good function of the wrist. Mechanoreceptors and proprioceptors are located in the ligaments and joint capsule of the wrist and provide feedback to the brain about the position of the joint and the speed of the motion being performed. They are also the pain feedback mechanism, and sense the pressure, torsion, and sensation to the joint, helping to prevent pain and injury. This also helps the body to recruit the appropriate amount of muscle contraction for movement.

Amy’s note: Therapists often appreciate the role of proprioception in the weight bearing joints such as the ankle, knee, and hip, but often will neglect the importance of proprioception in the wrist. With distal radius fracture, there is oftentimes ligamentous strain or disruption which can temporarily or permanently damage the mechanoreceptors and proprioceptors of the wrist. Muscles can serve a protective function in the face of ligamentous disruption, which is why understanding the complexity of the system is so crucial. The components of proprioception must be addressed in treatment in order to regain full joint control for a patient to truly “return to normal.” We will discuss this more under treatment.

Normal Movement Patterns of the Wrist

The three most commonly discussed movements of the wrist are flexion/extension, radial/ulnar deviation, and pronation/supination. The final motion is termed dart-throwing motion (DTM) and is a combination of flexion/extension with radial/ulnar deviation. DTM is an oblique plane of motion that is most commonly used in functional activities, and should be understood in order to effectively treat patients with wrist fractures correctly and with less pain.

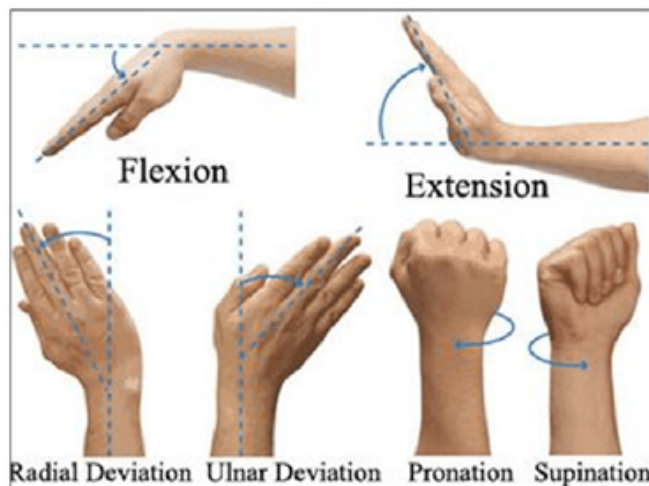
Flexion and Extension: During active or passive flexion of the wrist, the lunate translates dorsally and the capitate rotates palmarly. The dorsal radiocapitate (DRC) and dorsal intercarpal (DIC) ligaments prevent excessive rotation of the lunate and prevent volar intercalated segmental instability (VISI). With extension, the lunate extends and translates palmarly, and the capitate

rotates dorsally. They are check-reined by the palmar radiolunate ligament, preventing dorsal intercalated segmental instability (DISI). VISI and DISI will be discussed further in the context of complications. Pure flexion and extension of the wrist are the simplest motions to describe.

Radial and Ulnar Deviation: With radial deviation, the proximal row of the wrist actually slides in an ulnar direction while the distal row moves to the radial side. The scaphoid flexes during radial deviation, and as long as the SL and LT ligaments are intact, “pulls” the lunate and triquetrum along with it into a flexed position as it slides to the ulnar side. The proximal row basically has to flex and pronate slightly with radial deviation while the distal row slightly extends and supinates. This is an extremely complex maneuver.

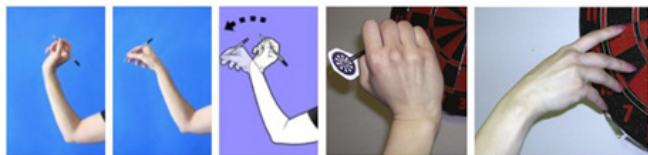With ulnar deviation the opposite is true: the proximal row slides in a radial direction and the distal row moves ulnarly. The compressive force of ulnar deviation causes the triquetrum to extend, and as long as the LT and SL ligaments are intact, the triquetrum “pulls” the lunate and scaphoid into slight extension and supination. The distal row reacts by ligamentous force to slightly flex and pronate.

Pronation and Supination: Forearm rotation is not technically a “wrist motion” but can be affected greatly by distal radius fracture due to the role of the distal radioulnar joint. Pronation and supination occur at the distal radioulnar joint (DRUJ) and the proximal radioulnar joint (PRUJ). At the DRUJ, the ulnar notch is the articulating surface located at the end of the radius, which travels around the distal end of the ulna with pronation and supination. This works in conjunction with the PRUJ to provide forearm motion.



Dart-Throwing Motion: As mentioned earlier, the dart-throwing motion (DTM) of the wrist is the most function-based description of true wrist motion in daily life. It is a multi-planar movement of radial extension and ulnar flexion. Researchers have discovered that most functional tasks are performed in a plane between 40 degrees of wrist

extension with 20 degrees of radial deviation, and zero degrees of flexion with 20 degrees of ulnar deviation (Palmer, 1985). When analyzed and compared to “truer” planes of motion (flexion/extension, and radial/ulnar deviation), DTM was found to require less scaphoid and lunate motion with more mid-carpal motion, resulting in less pain in patients with wrist injury or instability (Crisco, et al, 2005).



Amy's note: Since incorporating DTM active and passive range of motion exercises into my practice of treating distal radius fractures and educating my patients to the importance of using DTM, I have seen a significant decline in patient complaints of sharp pain. This seems to especially be the case during manual stretching for flexion and extension and causes me guilt for not knowing about it sooner in my practice. Patients tend to tolerate a DTM extension stretch MUCH BETTER than a prayer stretch. Try it out!

III. Wrist Fractures

It is more common to see fractures of the distal radius due to the fact that the end of the bone is more cancellous (softer) when compared to the shaft of the bone which is made up of more cortical bone. The good news is that the end of the bone also has greater blood supply, which means it will heal faster.

Classifications

The Frykman classification system is the most commonly used classification system for fractures of the distal forearm. The system takes into account several factors that affect predicted outcomes such as the degree of dorsal angulation, the degree of impaction, the degree and direction of displacement, the location of the medial fracture line (in other words, does it involve the radioulnar joint), and the presence of intra-articular fractures such as ulnar styloid fracture.

The Frykman classification progresses from the most simple fracture radiographically (Type I) to the most complicated (Type VIII). Be aware that this does not reflect the degree of intra-articular injury, comminution, or displacement, but rather gives information regarding just the structures involved. The descriptions for each type are as follows:

Type I: transverse metaphyseal fracture (Colles and Smith fractures)

Type II: type I + ulnar styloid fracture

Type III: fracture involving the radiocarpal joint (Barton, Reverse Barton, and Chauffeur fractures)

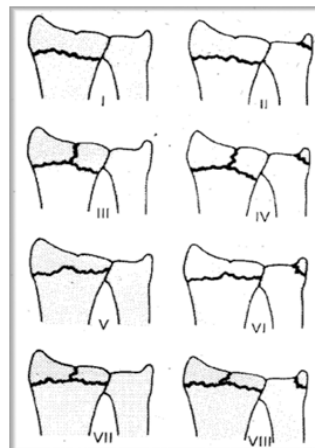
Type IV: type III + ulnar styloid fracture

Type V: transverse fracture involving distal radioulnar joint

Type VI: type V + ulnar styloid fracture

Type VII: comminuted fracture involving both the radioulnar and radiocarpal joints

Type VIII: type VII + ulnar styloid fracture



The Fernandez classification system is also widely used and is based on mechanism of injury.

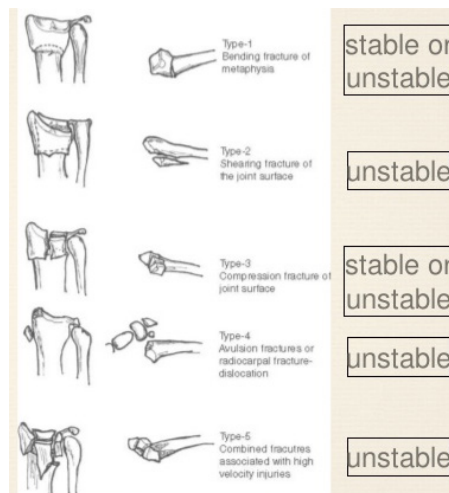
Class 1 - Bending: One cortex of the metaphysis fails due to tensile stress and the opposite cortex undergoes some comminution (Colles and Smith fractures)

Class 2 - Shearing: This is a fracture of the joint surface (Barton fracture, reverse Barton, simple articular fracture)

Class 3 - Compression: Fracture of the surface of the joint with impaction of subchondral and metaphyseal bone (die-punch), intra-articular comminuted fracture

Class 4 - Avulsion: fracture of the ligament attachments to the ulnar and radial styloid process (radiocarpal fracture/dislocation)

Class 5 - Combination of types 1-4 from high-energy injuries.



(Both classification systems are available, copyright free, at www.eatonhand.com.)

The [AO Foundation](http://www.ao.org) is a worldwide group of surgeons that focus their research on fracture management. They have been the longstanding experts on medical treatment, surgeries, implants, and all things related to fractures. The AO Foundation has a comprehensive alpha-numerical classification system for distal radius fractures which has recently been revised as of January 2018. Fractures are divided into extra-articular, partially articular, and complete articular fractures. They are further divided by ulnar involvement and number of fragments.

Amy's note: the information pertaining to the revision is just being released as of the writing of this course. You can use the image below as a reference, but should also visit www.aofoundation.org or search for "AO classification for distal radius fracture" for the very latest information, and/or to clarify the classification noted in your surgeon's records.

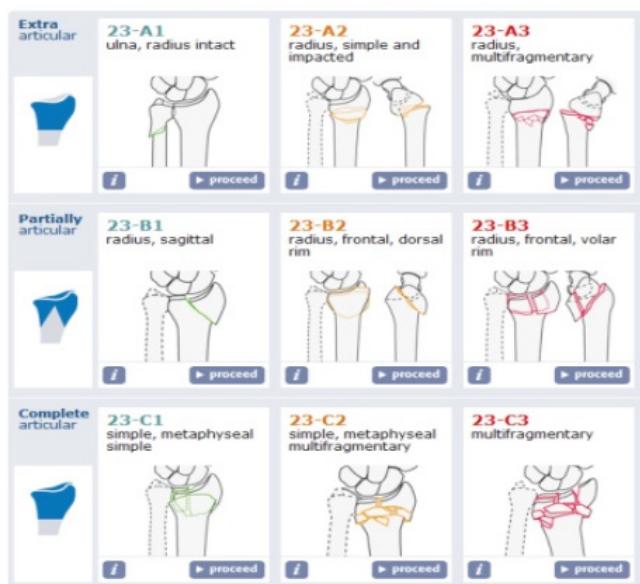

Image courtesy of orthobullets.com

Mechanisms of Injury

Most distal radius fractures occur due to a fall on an outstretched hand (FOOSH), but can also occur due to a crush injury, impact from a car accident, or other traumatic incident. Most injuries occur from a standing position. Naturally, a higher velocity fall tends to result in a more complicated fracture; younger patients tend to have higher velocity falls than older patients as a general rule.

Occurrence/Epidemiology

Distal radius fractures are one of the most common types of fractures in the United States, accounting for 15% of all fractures in the emergency room (Davis, 2010). Distal radius fracture as a diagnosis is bimodal in nature, as it occurs most often in young people and in the older

population. 25% of pediatric fractures are at the distal radius and are due to falls during sports, playing, and car accidents, and trends have shown a steady increase in the incidence of DRF in children over the past 40 years (de Putter, et al., 2011). In patients over 60 years of age, they are second only to hip fractures, and most commonly are due to a fall on an outstretched hand from a standing position. We have seen a greater frequency of this in recent years due to the overall aging of the baby boomer generation and their increased level of activity compared to generations previously. Some theorize that childhood obesity and the increase of osteoporosis have increased the incidence of DRF as well. Researchers suspect that changes in our dietary habits, metabolic rates, and lifestyle choices have increased our likelihood of fractures in general (Nellans, et al, 2013). Some researchers believe the overall increase in frequency is due in part to better access to care and improved diagnostic tools that allow us to appreciate non-displaced fractures more readily (Mathison, 2010).

Age, gender, and ethnicity play the largest roles in the epidemiology of distal radius fractures. As we've already discussed, children and the elderly are at greater risk for distal radius fracture than young adults. Longstanding research reveals that the peak age for girls is between the ages of 8-11 and for boys it is 11-14. Along with the high velocity falls, researchers have noted a correlation of bone mineral density to be directly related to the peak ages for falls in pediatrics. As children go through growth spurts in early puberty, they have large rates of bone lengthening with almost no change in bone mineral density, putting them at greater risk for fracture specifically of the long bones of the body (Faulkner, 2006). Even low-velocity injuries or minor traumas can cause distal radius fracture in this population. When comparing DRF by gender in pediatrics, 64% occur in boys (Ryan, 2010). Once patients get into their fifties the incidence swings greatly to women, with some studies reporting women suffering distal radius fracture almost twice as often as men (Chung & Spilson, 2001). Trends show that this frequency doubles every decade, and by the time a woman is in her nineties, she is five times more likely to have a distal forearm fracture than a man (Brogen, 2011). Chung and Spilson also report that Caucasians represent 83% of DRF presented to emergency rooms in the United States. Researchers are unclear if this is due to ethnicity or the fact that Caucasians make up the majority of emergency room patients.

Interestingly enough, elderly patients with cognitive decline are less likely to fall on an outstretched hand than their counterparts with no cognitive decline, resulting in lower incidence of DRF in that population. Researchers theorize that elderly patients without cognitive decline tend to walk more quickly, therefore putting them at greater risk for falling on an outstretched hand. Patients with cognitive decline tend to have slower reaction times to falling and therefore have higher incidence of hip and proximal humeral fractures with falls.

There are significant socioeconomic considerations with regards to distal radius fracture. Not only do patients have to pay medical bills for fracture bracing, surgery, prescriptions, therapy, and hospital bills, but patients are often out of work for several months due to injury. This leads to lost wages, lost time at school, and loss of independence which may require the patient to have more indirect costs due to injury than the cost of the injury itself. Because of this, patients are generally motivated to participate in therapy to regain function as quickly as possible.

IV. Overview of Medical Intervention

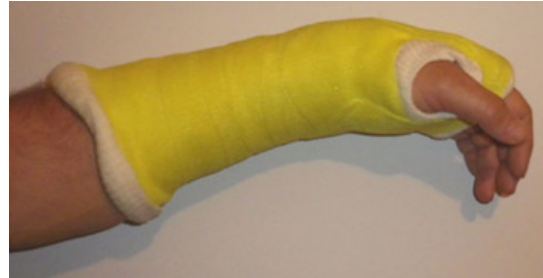In order for a fracture site to heal, it must be stable. In non-displaced fractures (fractures where the periosteum isn't disrupted and the bony fragments remain aligned), the bone simply needs to be stabilized for a period of weeks to allow healing. This is most often done with casting or orthotics. In fractures with fragments out of alignment, the doctor must reduce the fracture ends and provide some sort of stability through external or internal support. The physician's goal is to reduce the fracture the best he can so that healing occurs without bony angulation or rotation, which can affect functional outcomes and movement.

Non-Operative Treatment/Casting/Immobilization

Casting is the treatment of choice for fractures that are non-displaced. The fracture site will go through several phases of healing before it is stable enough to withstand active motion and eventually strengthening. The first seven days after the fracture, the site enters the inflammatory phase where the body forms a hematoma to provide early fracture stabilization and extra blood supply. The next phase is the repair phase, where the damaged cells are removed from the site and replaced with callus bone. The body continues to provide extra vascularization during this time. The repair phase can last between 6 weeks and 4 months depending on the site of injury, but most non-displaced distal radius fractures are healed within 6-8 weeks. Children heal more quickly, generally in about 4-6 weeks (Cooper, 2014). The callus continues to harden throughout this time, and eventually the body begins the remodeling phase in order to return the bone to its original strength.

The most common type of distal radius fracture is the Colles fracture, and these occur in postmenopausal women with osteoporotic bone (Medoff, 2011). The majority of distal radius fractures are treated with immobilization (casting) from the proximal forearm and extending distally to the metacarpal heads. The wrist is placed in slight flexion and ulnar deviation in the "Colles cast" position in order to use the surrounding soft tissue to help maintain the fracture reduction (Maheshwari,

2012). This position has been the position of choice for many years, but is coming under scrutiny now, as some physicians are reporting better functional outcomes with casting in a functional position.



The course of treatment for extra-articular, stable fractures has been closed reduction and casting for 2-8 weeks depending on x-ray results during follow-up (Medoff, 2011). However, Cochrane reviews have repeatedly come up short on the scientific evidence supporting the ulnar flexion position for casting. New research is ongoing and will take several more years of review before we can assume that physicians will be casting in a more functional position (less wrist flexion). One large prospective study is using the results from the Patient Rated Wrist Evaluation (PRWE) and Disabilities of the Arm, Shoulder and Hand (DASH) screens over a period of the next couple of years to help determine which position yields the highest functional outcomes (Raïttio et al., 2017).

Amy's note: As therapists, we begin battling the effects of ulnar flexion casting immediately upon removal, as this position often results in wrist stiffness and contractures in flexion, median nerve irritation, and poor gliding of flexor and extensor tendons. Not only is the wrist put in a provocative position, but casting past the MP heads makes MCP stiffness a significant factor in functional return. It seems from a clinical standpoint that if bony alignment can be achieved with a functional position, patients would have far fewer complications from casting. We simply do not have the data yet to support functional positioning vs. the Colles position.

Positioning is not the only culprit in causing stiffness. The protocol for length of immobilization has long been an area of interest for research studies. Patients, physicians, and therapists alike would love to lessen the length of casting to return to functional use as soon as possible. However, reducing the time of immobilization has not been met with overwhelming favor. Research suggests that functional outcomes for patients with moderately displaced fractures are indistinguishable between patients who have casts removed at ten days post-injury vs. one month, and removal of the cast in the early stages results more often in treatment failure (Christersson, 2017). In other words, although we would assume that removal of the cast earlier (when x-rays show callus formation at the fracture site) would avoid the complications of wrist and finger soft tissue adhesions and result in better functional outcomes, the data suggests that patients may initially have better function, but have a greater risk of

overall treatment failure (displacement of the fracture). Functionally, even though longer casting results in tightness initially, there is little to no distinguishable difference in use of the hand upon discharge, thereby leaving us back at square one with a typical timeline of about 6 weeks of immobilization for a moderately displaced fracture.

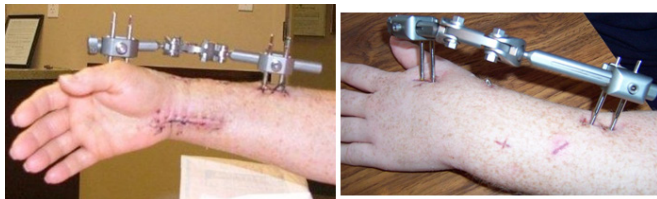Clinically, we must follow our physician protocols, and regardless of when the cast is removed, the therapist should be vigilant in monitoring patient complaints, swelling, or sensory changes in the initial stages of treatment. Clarify the physician orders with the doctor to ensure that treatment isn't too aggressive too soon.

Surgical Treatment of Fractures

Surgical intervention is required for fractures that are displaced, or when several fragments of the bone have occurred. Internal fixation can potentially speed up the course of treatment as it provides the support that the body creates using callus formation, essentially bypassing the need for this system. If the physician is able to realign the fragments with adequate compression and stability, and the fragments have good blood supply, the body will avoid the callus formation stage and move into the final stages of healing. This helps reduce edema, and allows for earlier initiation of motion, which helps get the patient back to functional activities sooner.

Closed Reduction External Fixation: Closed reduction with percutaneous pinning in addition to casting is indicated with extra-articular fractures without significant metaphyseal comminution or in the case of two-part intra-articular fractures. Typically, pins are placed for 4-6 weeks, and ulnar-based casting or splinting is indicated for 6 weeks. Active range of motion begins after the cast is removed and therapy is progressed as per physician protocol after that.

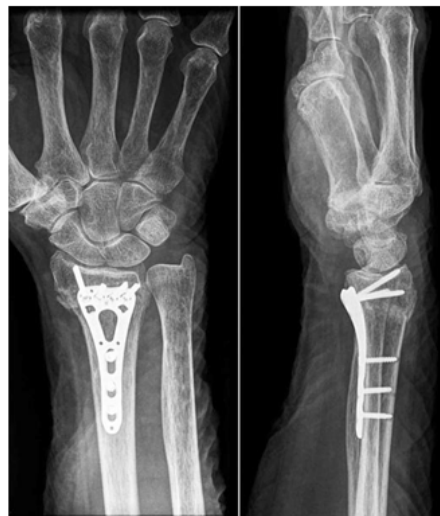Spanning external fixators are sometimes used in conjunction with percutaneous pinning, depending on the severity of the injury. Bone graft and bone graft substitutes can also be used to augment treatment times with percutaneous pinning. External fixation is the treatment option of choice when the fracture is comminuted and the surgeon cannot place an internal plate in the associated fragments. It is also used when traction across the joint cannot be maintained. The positive side of using external fixation is that the hand is easily accessible for wound care (when compared to plaster or fiberglass casting), and the fingers are typically more free than with casting so that patients do not develop secondary stiffness to the digits.



Some of the most common complications with external fixation are nerve irritation to the median nerve or the dorsal sensory branch of the radial nerve, damage to nearby tendons, musculotendinous tightness of extrinsic and intrinsic muscles, and pin tract infections (Mischlovitz, 2011). These complications will be discussed in more detail later in the course.

Open Reduction Internal Fixation (ORIF): Open reduction and internal fixation (ORIF) is considered the treatment of choice when more conservative treatments such as casting fail, the fracture is unstable, or reduction is poor. "Poor reduction" consists of more than 10 degrees of dorsal angulation, more than 5 degrees of radial shortening, or there is significant comminution. The primary goals for internal fixation are to maintain radial length through traction and reduction of the fracture.

The Volar Locking Plate (VLP) is the gold standard treatment for open reduction and internal fixation of distal radius fractures and has been used more and more over the past decade. Volar fixation is now considered preferable over dorsal fixation, as studies show less complications of tendon disruption with volar plate fixation (Orbay, 2006). Functional outcomes and quality of life are significantly better for patients with intra-articular DRF after volar plate fixation compared with conservative fixation with plaster casting or external fixation. Restoration of the articular surface, radial inclination, and ulnar variance is much more precise with open repair vs. conservative casting, not to mention that conservative casting in these cases can often lead to treatment failure (loss of reduction of the fracture) (Martinez-Mendez, et al. 2017). Lower profile plates have decreased the discomfort of the appliances and have become a much more popular treatment for many surgeons.



Surgical fixation can be advantageous in many ways; however, complications can occur because of it. Increase bulk in the wrist despite the low profile can cause discomfort for gliding tendons. Dorsally placed plates and screws tend to cause more discomfort than volarly placed

ones and sometimes will need to be removed after the fracture is healed. The extensor pollicis longus tendon is at a particular disadvantage with dorsal fixation, as it can sometimes get trapped under the plate, or rub against the plate causing irritation or even rupturing. Other disadvantages to surgical fixation are the increased potential for infection and increased scarring due to surgery itself.

Amy's note: Clinically patients tend to tolerate volar plate fixation very well (in comparison to external fixation). After recovering from the initial post-operative soreness, patients tend to report feeling more "stable" in the wrist than their counterparts who are casted for multiple weeks, resulting in better compliance with exercise, activity, and functional use of the affected arm.

Patients should be educated to avoid gripping or lifting until the physician clears them for strengthening, as the fixation is not strong enough to maintain more force than 36 pounds per square inch (Cooper, 2014). This can be difficult for a patient to gauge, so a conservative approach of no lifting or gripping would be the preferable treatment option to avoid fixation failure. Metal plates are also not strong enough to maintain their position with weight bearing, and patients and therapists should be aware of this.

External vs. Internal Fixation: A large meta-analysis completed by Wei, et.al. (2012) of 12 research projects (covering over 1,000 patients with surgical intervention) compared the outcomes of patients who underwent ORIF with patients that had external fixation for unstable distal radius fractures. Overall, the patients that underwent ORIF had significantly better functional outcomes, more forearm supination mobility, and better restoration of anatomical volar tilt. However, the patients that underwent external fixation had better grip strength and wrist flexion mobility. Patient outcomes with regards to pain and function were indistinguishable using the Visual Analog Scale (VAS) and Patient Rated Wrist Evaluation (PRWE). Therefore, there is still no statistical consensus as to which procedure yields the best results. Surgeons must make a judgment call as to which treatment option will not only provide the best outcome, but which goals are most appropriate for the patient.

V. Rehabilitation/Healing Timeline

In general, most fractures heal within about 8-12 weeks (Cooper, 2014). Most patients are not referred to therapy until fracture healing is certain, but occasionally physicians will refer patients for swelling or complications prior to removal of immobilization for therapy to begin. Ideally, all patients would be seen within a week of immobilization so that therapists can orient their patient to edema control techniques and ADL adaptation ideas for living one-handed for several weeks. (This is definitely a good marketing tool for any therapists looking to educate their doctors on the importance of treatment.)

In the event that the patient had no initial complications during the immobilization phase, patients usually get referred for therapy the day their immobilization is removed. They usually are seen for an initial evaluation within 1-2 days of cast (or pin) removal. Depending on the physician's prescription, patients usually begin active range of motion (AROM) around 3 weeks after immobilization is removed if the patient had external fixation or casting. If the patient had internal fixation (volar plate), AROM can begin around 1 week after surgery. Progress to passive range of motion (PROM) of the wrist around 2-3 weeks following AROM exercises as needed to resolve stiffness. Strengthening is typically started around week 8-10. Always remember that with distal radius fracture, the natural progression of treatment at the wrist is AROM, then PROM, then strengthening. Other joints may follow a different track, but the injured wrist joint should be progressed in this order.

Evaluation for Rehabilitation

Gathering History

The first vital piece of information when gathering your patient's history is an account of the actual injury itself. We know that most distal radius fractures occur from a FOOSH, but there is a lot more information that can be gleaned from hearing about the injury. Have the patient describe the injury or accident to you so that you can get a clear picture of the direction of force over the wrist, the relative velocity of the fall, and any other specifics that can affect your treatment, such as the precipitating factor in the fall. Did your patient lose her balance for no particular reason, trip over a throw rug, or fall down the stairs? Was she adjusting to a new medication or did the dog walk out in front of her? You may find that performing a fall risk assessment is wise to prevent further injury. This also helps you treatment plan any home modifications that may be necessary to avoid future falls.

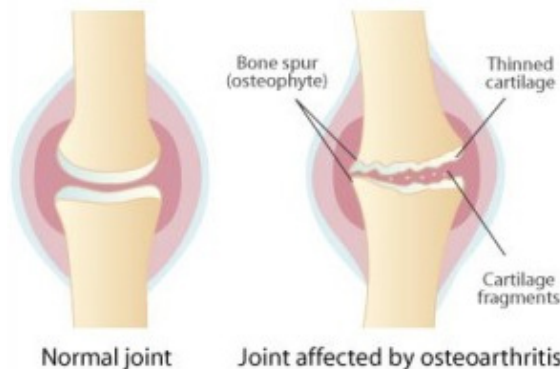
After gathering the history of the fall, getting a full and accurate medical and surgical history is next. Does the patient have any other known medical conditions such as osteoporosis, osteopenia, or diabetes that will affect her rate of healing? Does she have a history of falls, dizziness, or head injury, or use psychotropic or cardiac medications that would cause dizziness or light-headedness? Has she ever injured this wrist or any other part of the affected UE prior to this injury? Are there any other known issues besides the wrist fracture, like an elbow fracture, humeral fracture, rotator cuff tear, or labral injury? Does she have a previous surgical history involving her neck or UE? Any underlying osteoarthritis or disc compression? All of these things can affect your patient's return to full function and also the course of treatment you are providing. Other factors that can affect healing times are tobacco and alcohol use, and general nutritional health. Does your patient take any supplements of which you need to be aware?

A comprehensive checklist of known complicating

diagnoses can easily be filled out by your patient prior to her initial evaluation. Medical conditions to consider are osteoarthritis, rheumatoid arthritis, osteoporosis, osteopenia, anxiety disorders, lymphedema, fibromyalgia, history of previous complex regional pain syndrome (CRPS), previous UE or neck injuries, carpal tunnel syndrome, diabetes, cancer, and history of self-harming/dissociation. Make sure to allow room for “other” on your list so that patients can go into detail and/or give you approximate surgical dates. Some significant diagnoses surgically would include any previous fractures of the UE, mastectomy or lumpectomy, cervical fusions, carpal tunnel release, trigger fingers, or any joint replacements in the hand.

Co-morbidities

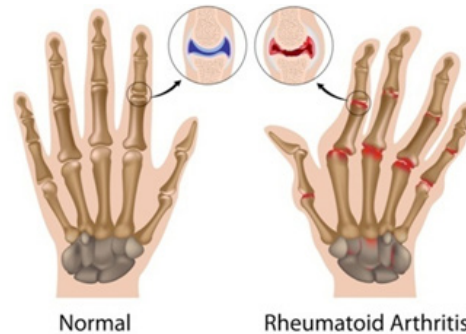
Osteoarthritis: Osteoarthritis occurs when the cartilage that cushions the ends of bones in synovial joints gradually deteriorates and becomes rough. As the cartilage starts to deteriorate, movement/activity causes increased friction on the two ends of the bones, which irritates the cartilage even more, causing the “wear and tear” to the joint surfaces. Eventually, if the cartilage wears down completely, the patient has bone rubbing against bone, which is typically (but not always) painful.



It is important to be aware of a history of OA in the wrist or fingers with your patients with distal radius fracture as this will affect your treatment regimen and your patient’s tolerance for activity and manual treatment. Joints with articular breakdown should be handled carefully, making sure that you don’t put too much stress using PROM, joint manipulations, or repetitive exercise which can exacerbate pain related to the arthritis. Oftentimes patients with underlying asymptomatic osteoarthritis may suddenly develop joint pain as a result of an injury, so it is not enough to ask the patient if they have OA, but rather, clarify with the physician if OA has been identified on x-ray or other diagnostic scans.

Amy’s note: Patients will often ask if they are going to develop arthritis after injury. While patients do have a higher risk of developing secondary arthritis, particularly patients with intra-articular fractures, this question should be deferred to the physician so as to not cause any confusion or conflicting information.

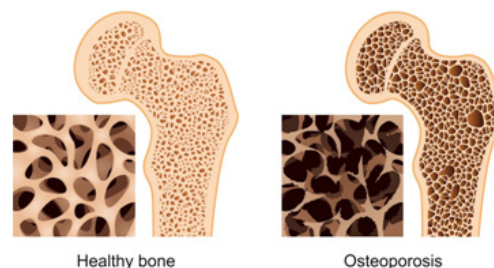
Rheumatoid Arthritis: Rheumatoid arthritis is an autoimmune disorder; increased healing will need to be factored in when deciding on a timeline of return to functional activity, as patients with RA tend to heal more slowly than their fellow patients. Many patients with RA also have other autoimmune diseases which can slow healing times as well.



As with osteoarthritis, PROM of joints in patients with rheumatoid arthritis is contraindicated due to the enzymatic breakdown of the joint tissue and subsequent ligamentous and tendinous mal-alignment that is accompanied with it. Passively stretching patients with rheumatoid arthritis should be done with extreme care, as this could exacerbate alignment dysfunction and cause more pain and disability for patients. Not only can overstretching cause alignment issues, it has also been known to “flare up” RA that is currently dormant.

If you are unsure how your patient’s RA will affect their treatment, discuss your concerns and course of treatment with the surgeon or physician.

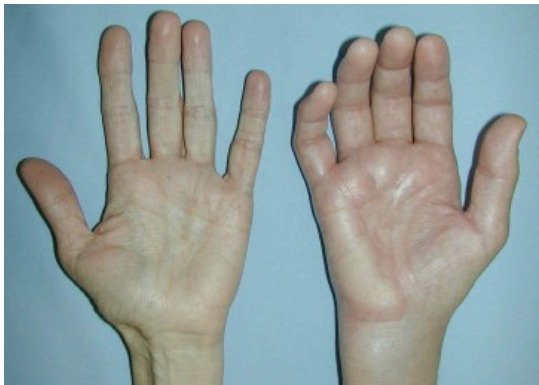Osteoporosis: Osteoporosis and osteopenia are common degenerative changes noted in the elderly population, where the body has a reduced capacity to rebuild or remodel bone. Not only is osteoporosis a positive predictor for increased likelihood of distal radius fracture, but it directly correlates to the increased severity of fractures and increased incidence of intra-articular fractures. Osteoporosis also increases the incidence of early instability in closed reduction cases (casting) and late carpal malalignment. In short, patients with underlying osteoporosis are more likely to fracture at the distal radius and more likely to have complications compared to healthy patients. The relationship between osteoporosis and DRF is strong enough that elderly men who present with DRF should be evaluated for osteoporosis as their risk for hip fracture is also greater (Munk, 2007).



Fibromyalgia and CRPS: Although we do not have good research or answers on what causes a patient to develop complex regional pain syndrome (CRPS) after injury, and researchers are unsure how or why CRPS and fibromyalgia are linked, we do know that patients with a history of fibromyalgia have a higher incidence of developing this painful complication. Likewise, patients with a history of anxiety disorders also have an increased risk of development of CRPS (Lipman, et.al., 2017). CRPS causes central sensitization, which is a loss of brain-orchestrated pain inhibitory mechanisms and hyper-activation of the ascending pain pathways. In other words, the body perceives otherwise normal stimuli as painful, and responds with severe pain.

If the patient has a history of CRPS or fibromyalgia, and/or anxiety disorders, the therapist should be hypervigilant in watching for the tell-tale signs of developing CRPS. This can happen at any time during the course of treatment. Common symptoms are:

- Shiny, wax-like skin
- Increased vasomotor instability (blue or red skin color changes)
- Increased sympathetic activity such as profuse sweating of the UE
- Temperature differences between the affected and unaffected side
- Brawny edema
- Unrelenting stiffness
- Decreased ability to sleep
- Increase in pain levels



As the therapist can see, CRPS causes other symptoms in the patient besides the physical changes in the extremity. Patients begin having difficulty sleeping, making them more irritable and less tolerant of pain. Patients can also begin having increased anxiety, forgetfulness, and loss of concentration. Patients may have increased difficulty remembering their home programs and even clinic exercises because they become consumed with pain. They report that they feel “out of control” in many area of their lives as the symptoms persist.

If these symptoms present themselves, contact the physician to discuss your findings. Medical treatment will most likely be modified to address and hopefully resolve the CRPS before it becomes debilitating. Rehabilitation strategies to address and/or avoid CRPS include a stress loading program, functional activities, desensitization, and graded motor imagery.

CRPS is difficult and frustrating to treat, as it presents differently in every patient and takes many months to resolve, if it resolves at all. The most important part of treatment is to maintain as much functional use of the hand as possible so that the patient has limited residual stiffness and muscle atrophy as the CRPS resolves. Patients do not respond well to any passive treatment such as manual soft tissue mobilizations, joint mobilizations, or passive range of motion. Even when the patient does not complain of pain during these activities, they will oftentimes have a rebound and exacerbation of symptoms following a manual treatment.

Education on the progression and the mechanism of injury for CRPS is vital in helping patients deal with their symptoms. The therapist can assist with this by providing sound medical advice about CRPS, helping the patient find a support group if need be, and continuing to offer the patient moral support and autonomy to self-direct their therapy.

Amy's note: If you suspect that your patient is developing CRPS-like symptoms, immediately adjust your treatment plan to a self-directed list of various functional activities, stress loading program, and graded motor imagery protocol. Allow your patient to work at her own pace and her own comfort level, which will most likely change from treatment to treatment. Although your patient may not get “full range of motion” or seem to be making significant gains, the premise behind this type of treatment is that you are reducing the central sensitization that has occurred in the brain. Patients need to be reminded to respect their body, and that they have total control over their rehabilitation.

I usually put together a clipboard of suggested activities including desensitization, stress loading, fine motor, gross motor, open-chain and closed-chain activities, and even online apps and games to play. My patients are told to do the activities in any order they please at whatever pace they please and to report back how they are feeling. I stress the importance of laterality training, visualizing the affected side doing pain-free activity, and mirror therapy (the three phases of graded motor imagery, or GMI) to reduce their disability long-term. Patients respond very favorably to GMI as it isn't painful. More information on GMI can be easily accessed online.

Lymphedema: Patients with a history of lymphedema will need extra care and attention toward their edema management, as swelling is the complication that most commonly affects functional outcomes in patients with distal radius fractures. Discuss your patient's current lymphedema management strategies, and

review and emphasize the importance of consistent diaphragmatic breathing, proximal lymphatic drainage strategies, and careful compliance with edema management specific to the wrist and hand to ensure that your patient is getting adequate lymphatic exchange. Make sure to educate your patients who feel that they have their lymphedema under control that an onset of new injury can exacerbate their symptoms. Lymphedema management takes diligence and consistency and should not be overlooked in this population.

Other pertinent questions and considerations:

- How long was the patient immobilized?
- What type of immobilization?
- Did the doctor provide the patient with instruction on how long to wear the immobilization?
- Have there been follow-up x-rays and what is the doctor's report from these?
- Can you obtain a report from the physician verifying the results of the latest x-rays?
- What medications is the patient taking for the injury, and at what dosage?
- Any current or previous use of a bone stimulator?

Clarification with MD

Although some of the items on this list are questions you might ask the patient, there are times when a patient doesn't have all of the information, especially when discussing the intricacies of their injury. Patients tend to have very little anatomical knowledge of their injuries, so they may not be able to provide accurate answers to these questions. If you suspect your patient doesn't have a complete working knowledge of their condition, make sure to clarify with the physician by asking for an operative report. If your patient has had surgery, it is valuable to have a copy of the operative report in your file to refer to during the course of treatment.

Some clarifications to be obtained from the physician:

- Does the patient have any notable joint breakdown not related to the fall?

As discussed previously, recognizing any underlying osteoarthritis or joint deformities will be helpful in not exacerbating joint irritation during treatment. Most distal radius fractures happen in post-menopausal women. It can be assumed that many of them have joint breakdown whether or not they know it.

- Is there intra-articular extension of the fracture?

This increases your patient's risk of developing arthritis and also suggests a more complicated fracture with increased healing times.

- Is there any expected disruption in radial length, inclination, or tilt? Does the physician feel confident

that the patient will regain full motion in all directions?

Keep in mind that the physician will know best what the patient's available range of motion will be, because he is able to ascertain that during surgery through PROM evaluation while the patient cannot feel anything. Tissues are relaxed, pain is blocked, and there is no edema present. If the physician cannot achieve full PROM under those conditions, then the patient will not regain full active range of motion. The surgeon will also know if he was able to achieve excellent alignment of the fracture pieces, giving you a better indicator of how successful the treatment will be.

- Will hardware be removed during the course of treatment?

Even internal fixation can be used with the expectation of removing it after the patient has full fracture healing. Although the intent is typically to leave the hardware in place permanently, patients can develop excessive scarring, nerve irritation, infection, and other soft tissue compromise that make leaving the hardware in place more detrimental than removing it. Unfortunately, this requires another surgery, but sometimes is the best case scenario in order to restore bony alignment early on in the healing process.

- Does the doctor have a specific post-op protocol following her medical treatment that she would like you to follow?

Outlines given in this course are generalities, meant to give you an idea of what is a typical protocol following immobilization or fixation. Your physicians most likely will have specific protocols that work best with their type of treatment. It is considered best practice to have a conversation with your referring physicians about what protocols they like to follow for rehabilitation following their fixations, including wound care and specific pin site care. If they do not have a specific protocol that they like to use, make sure to give them a general idea of the timeline you are considering to ensure that you are on the same page with regards to treatment.

For example, if you would normally start strengthening your patient at 8 weeks post-op, but you know your patient has a history of diabetes and osteoarthritis, you may decide that strengthening would not be appropriate until post-op week nine or ten. Discuss this rationale with your referring physician (either through a phone call or progress note) so that he can approve or adjust your timeline accordingly. More communication with your physician will lead to better outcomes and increased rapport with both your patients and referral sources.

- Are there any other known soft-tissue injuries related to the fall or noted on diagnostics that would affect the treatment timeline or protocol, such as TFCC derangement, ligament damage, nerve damage, or avascular necrosis? (These complications will be discussed in more detail later in the course.)

Functional Outcome Screens

Functional outcome screens are commonly employed in today's clinics to gain subjective and objective data from the patient that can be used as a baseline and to show improvement. Much of our research on the efficacy of treatment is based off of results from functional outcome screens. Physicians and payers can easily see a "snapshot" of a patient's status with some of the more commonly used functional outcome screens.

DASH or QuickDASH: The Disability of the Arm, Shoulder, and Hand (DASH) and QuickDASH screens are the most commonly used UE outcome measuring tools in the field today and were meant for patients between the ages of 18-65, although they can be used on patients outlying this age range. They are designed to measure the physical function and symptoms in people with UE musculoskeletal disorders. The DASH consists of 30 activities that a patient self-rates their level of difficulty performing on a scale from 0% (no difficulty) to 100% (unable to perform). It is important to note that these screens are DISABILITY ratings, so the higher the number, the more difficulty a patient is having. The QuickDASH is a condensed version of the same test, consisting of only 11 of the 30 activities. Both of these tests can be used without obtaining license, and can be accessed and scored online at orthopaedicscore.com. There is also an application on Apple products that is downloadable to use the screens on mobile devices. In addition, there are also two specialty modules that can be added to the DASH that include work or sports, depending on your needs.

The DASH and QuickDASH are simple to use, easy to understand, and give valuable data to the patient, therapist, doctor, and payer. These screens do not discriminate which hand is used in a task, just how easily the patient can get the task completed. This is different from some of the other tests we will review. A minimally clinically important difference (MCID) score exceeding a 15 point change is considered a significant change in function, while the minimal detectable change at the 95% confidence level (MDC95) is 13 (Hudak, 1996).

PRE or PRWE: The Patient Rated Evaluation for the wrist (PRE) or wrist/hand (PRWE) were developed by Joy MacDermid and her team almost 20 years ago and are still widely used today (MacDermid, Turgeon, Richards, Beadle, & Roth, 1998). Both of these tests would be appropriate tools to use to measure pain and functional disability outcome for patients with distal radius fractures. These tools are widely used in clinics and research for injuries of the hand and wrist and have been employed in dozens of clinical studies. Both tests are free to use and consist of 15 questions completed by the patient, with 5 dealing with pain and 10 dealing with function of ADL tasks. The MCID is calculated as 11.5 and the MDC is calculated at 11 (Walenkamp MM, de Muinck Keizer RJ, Goslings JC, Vos LM, Rosenwasser MP, Schep NW, 2015). The copyrighted version of the PRE and PRWE are free to use and can be found

at <https://srs-mcmaster.ca/research/musculoskeletal-outcome-measures/>.

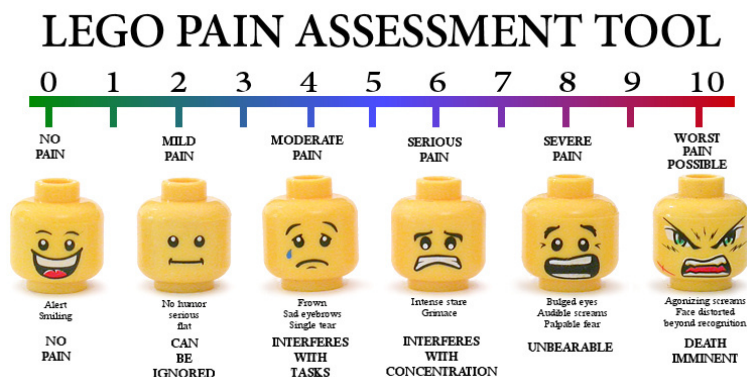
Michigan Hand Outcomes Questionnaire (MHQ): The Michigan Hand Outcomes Questionnaire is a 37-question, hand-specific outcomes instrument that measures disability. It is broken down into six domains: overall hand function, activities of daily living, pain, work performance, aesthetics, and patient satisfaction. The entire test takes about 15 minutes to complete. Each hand is assessed in each area except for work, and scores are reported for each hand, which makes this a good assessment to use to demonstrate the disability of the affected hand; the QuickDASH, by contrast, does not separate the affected hand from the non-affected in its assessment. The MHQ is considered a reliable, valid, and responsive instrument to assess hand function. It can help the therapist determine and document whether the injured hand and its dominance have had an overall negative effect on functional abilities.

This is a subjective test that is easy to administer and easy for patients to understand. The MHQ does require licensure to use, however copies of the MHQ can be found online in order to determine if this test would be useful in your hand therapy practice. It can be used for a wide range of hand injuries, not just for distal radius fracture.

Visual Analog Scale (VAS): A standard visual analog scale is a psychometric numerical rating scale that can be given upon evaluation and at each visit to assess a patient's pain level. The therapist asks the patient their pain rating on a scale from zero to ten, zero representing no pain and ten representing the worst pain imaginable. This is a subjective response on the part of patient, and is considered an accurate and reliable scale to measure a patient's pain level during a visit and between visits. This is the most widely used outcome screen across all medical disciplines and patients are very familiar with it.

Many patients understand the concept of the 0-10 numerical rating scale, but many visual representations of the scale can be found through an image search on the internet.

Amy's note: My favorite visual copy of the VAS is the LEGO pain assessment tool, created by Brendan Powell Smith (www.TheBrickTestament.com). This chart is not sponsored, authorized, or endorsed by the LEGO Group. You're welcome.



Observation and Establishing Rapport

Patients with distal radius fracture tend to be nervous their first day of therapy and do not typically respond well to excessive measurements and manual evaluation. Reducing your amount of “hands-on” evaluation the first day can help establish rapport with your patient and put them at ease with the therapy process. Of course measurements provide valuable information, but establishing trust the first day is much more vital to the success of your overall treatment plan than painting the picture of the hand and wrist with number values. Good observation skills are vital to performing a thorough evaluation of your patient, and can be performed simultaneously with time spent taking the patient’s history.

Spending time observing the patient’s current acceptance of the injury, guarding patterns, swelling, trophic status, use of external support, incision health, and cleanliness provides a wealth of information on day one of treatment.

Guarding Patterns: Is your patient excessively guarding the hand by holding it against her body? Is she keeping the arm adducted and protected when she walks instead of allowing her arm to hang freely and swing naturally as she walks? Is she posturing with her elbow flexed most of the time to protect the hand? Does she avoid attempting to use the hand for normal tasks such as filling out paperwork? Is your patient willing to place the hand on the table for your evaluation? Does she seem nervous to allow you to move or touch her hand? Will she attempt to actively move the wrist and fingers when asked? All of this information allows you to get a sense of how much more objective assessment you can perform the first visit or two.

Swelling: In general, how edematous is the wrist? The hand? The fingers? Of course circumferential measurements can be of value, but if your patient seems hesitant to allow you to touch the extremity, then a general assessment through observation can be made the first day. Note any pitting edema, the severity of edema noted to the fingers and wrist (mild, moderate, severe), and talk to the patient about any edema management they’ve employed so far. Educate the patient that edema control will be a main goal of treatment, and controlling it appropriately is one of the primary indicators for long-term success.

Trophic Status: Compare your patient’s affected hand to the unaffected hand. Does it seem more purple, pink, or white than the other hand? Is your patient having increased sweating on one side more than the other? Do you notice any differences in skin texture or nail texture? Document any differences that you see and monitor these things as your course of treatment proceeds.

External Support: Did your patient arrive with any external support such as a pre-fabricated wrist cock-up splint or thumb spica splint? Is she wearing a sling to protect her upper extremity? Is the amount of support she

presented with appropriate for the injury? Some patients will over-guard their injury by wearing an unnecessary splint, while others could benefit from support but decide not to wear it. Compare the amount of support they are wearing with what you consider clinically appropriate for their stage and healing and address this opening with your patient. Patients with distal radius fractures often get dependent on fracture bracing much longer than is clinically necessary, and it is the duty of the therapist to help wean the patient out of the splint as soon as possible to avoid this dependency. Typically, patients no longer need external support after about 6 weeks post cast removal if they have had traditional casting, and can remove external support after about 3 with post ORIF. Obviously this can vary, but is a nice general rule of thumb.

If the patient is wearing an orthosis, the orthosis should be evaluated as well for proper fit and appropriate positioning. Ideally, patients will have about 30 degrees of wrist extension in their orthoses, but this is often not the case at the beginning of treatment. Patients are commonly casted in slight wrist flexion which leads to tightness in this position when the cast is removed. Initially providing a neutral wrist support is fine, but serially increasing the wrist extension to thirty degrees (eventually) should be part of the plan of care.

Along with wrist positioning, ensure that the orthosis is the correct size for the patient. Does it allow her to fully flex the MP joints of the fingers? In order for this to be the case, the therapist should be able to see the distal palmar crease when the splint is on. Also, if the physician is allowing full use of the thumb as able, the patient should be able to comfortably oppose the thumb to the tip of the middle finger. If the orthosis is too restrictive or too large, the patient could have unnecessary stiffness of the thumb and digits due to a poor fit. On the other end of the spectrum, if the orthosis is too tight, it can cause undue swelling to the fingers which will cause stiffness and pain as well. Adjust the splint as able, and if the splint cannot be adjusted adequately, consider replacing it with something more appropriate. An ill-fitting splint can affect a patient’s eventual outcome, so this should be addressed as soon as possible.

Incision Health: It is the responsibility of the therapist to monitor the health of the patient’s surgical incision (when necessary). Whether the patient has an associated wound from an open fracture or surgical incision with sutures, inspect the incision/wound for signs of infection. Any sudden onset of increased swelling, redness, purulent drainage, or even fever or malaise can be signs of infection in the wound and should be reported immediately to the physician. Do not remove sutures or steri-strips unless you have permission from the physician to do so. Pin sites are notorious for allowing bacteria to enter the skin and must be treated appropriately to avoid infection. Be sure to educate your patient to the signs of infection such as increased pain at the pin site, redness, increased swelling, purulent drainage, a foul odor, or increase in

skin temperature. Any red streaking should be addressed immediately by calling the physician, as this could be sign of an infection spreading into the bloodstream.

Cleanliness: Is the patient able to adequately clean the affected hand and wrist? If dressings are being used as with open fractures with associated wounds, are the dressings clean and appropriately applied? Has the patient been applying any creams, lotions, or gels to the incision or wound and are they approved by the physician? Many physicians have strict protocols on what is appropriate to apply to an incision, so clarify this with your patient and/or physician. If the patient has an external fixator, are they adequately caring for the pin sites as instructed by their doctor's office? Are they cleaning each pin site with a new q-tip and only using approved medications as noted by their post-surgical instructions? If you have any concerns in this area, be sure to address with the physician's office.

In addition, asking your patient about their lifestyle and goals is valuable in determining what is important to them. A good history can strengthen rapport and reveal a lot about a patient's motivation towards full recovery. This will be crucial to establishing appropriate goals and ideas for functional treatment. Commonly used in sales, a great way to get to know your patient is to ask them questions based on the acronym FORM:

- F: Family
- O: Occupation
- R: Recreation
- M: Motivation

Some of these topics are natural and seem obvious to the therapist, such as finding out what the patient does for a living and what he does for fun, but investigating what motivates a patient will help the therapist to understand what else will affect the patient's treatment. For example, patients are often not as concerned about returning to their desk job as they are being able to play catch with their grandson. Also, remember that it is our job to educate the patient to how to return to the highest level of function possible, but this may not necessarily be the goal of the patient. For example, some patients will sacrifice full motion just to be out of pain sooner.

In some cases, the history gathering can reveal "orange flags." Orange flags concerns can include items such as the patient has an upcoming vacation or holiday and doesn't want to recover too quickly so she doesn't have to return to work right away, or the patient reports that she never heals quickly and she doesn't expect to do well. These are concerns that can negatively affect the patient's outcome, but aren't necessarily as serious as "red flags." Red flags concerns are things like a patient who is counting on a large settlement for her injury, or a patient who hates her job and doesn't want to return to it. Any of these situations can lead to a patient not trying her best, or even sabotaging her recovery. Although we commonly think of these as intentional acts, they may or may not be consciously created by the patient. Open and honest communication with your patient about what you are

observing is the best form of treatment for a patient who is displaying orange and red flags. The sooner these issues are addressed, the less likely they are to affect the patient's outcome.

Objective Measurements

After a complete history has been taken and initial observations have been made, the therapist can begin the objective portion of the evaluation. Active and passive range of motion, joint integrity, extrinsic and intrinsic tightness, edema, median nerve gliding, fine motor coordination, and strength testing are all objective measurements that may or may not be appropriate during the initial evaluation. As we review these areas of assessment, be mindful that the physician's protocol may prohibit some of these assessments initially. Please clear active range of motion (AROM), passive range of motion (PROM), and strength testing with the physician prior to your assessment.

Active Range of Motion: Prior to assessing AROM, the therapist should make sure that the patient has been cleared by the physician for motion of all involved joints. Occasionally a patient will be sent to therapy prior to being cleared for motion of the wrist with an order to move the uninvolved joints. If you have any question on what your physician intends, please clarify before moving the wrist immediately after immobilization is removed.

AROM can be assessed during the initial evaluation in a variety of ways. There is no "right answer" for what is appropriate, as the therapist must take into account the patient's comfort level with the evaluation process. When a patient has extreme guarding and anxiety surrounding the evaluation, it is prudent to just take a general assessment of AROM of the hand, wrist and forearm. Asking your patient to "make the best fist you can" and placing a percentage value on that fist can be adequate for day one. For example, if the patient can barely move her fingers at all for whatever reason (pain, fear, joint stiffness, extrinsic tightness, etc.), the therapist may document this as "The patient is unable to make a 25% fist." Although inter-rater reliability is low for this type of assessment, the therapist can always clarify in subsequent visits the patient's actual AROM for the fingers.

The same strategy can be used for measuring wrist flexion/extension, radial/ulnar deviation, and forearm pronation and supination. Ask the patient to perform the motion and give a general assessment for those motions. The therapist typically will combine opposing motions and document it as such, "The patient has about 50% total wrist flexion/extension and RD/UD" or "The patient has extremely limited pronation and supination due to severe guarding and increased anxiety. Actual numerical AROM measurement will be taken over the course of the next 2-3 visits as patient comfort allows." This provides the information to your ordering physician and payers that you are addressing the issue but are considering the well-being of your patient as your primary concern.

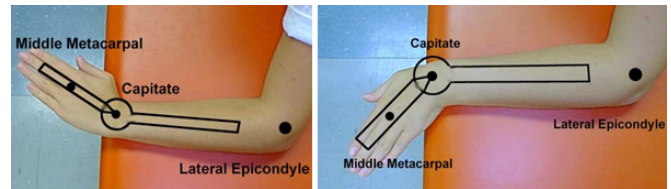
When your patient has been cleared by the physician for movement and is agreeable to goniometric evaluation, whether that is on day one or any subsequent day of treatment, all measurements should be taken using the American Society of Hand Therapists (ASHT) Guidelines outlined in Edition 3 of the “Clinical Assessment Recommendations for Hand Therapists.” Any deviations outside of these approved measurement guidelines should be documented in the patient’s chart in order to increase inter-rater reliability if your patient is seen by another therapist.

Wrist Flexion/Extension: Wrist flexion and extension should be measured with the stationary arm of the goniometer along the forearm, and the movement arm should be along the third metacarpal. The axis should be sitting either dorsal or volar to the capitate bone which sits just proximal to the third metacarpal. A small gap is common at the axis of the goniometer where it will not touch the skin of the patient: this is normal. Many therapists measure flexion and extension along the ulnar aspect of the hand and forearm; however, this skews the results when compared to normative data. If the patient has an open wound that makes measurement over the third metacarpal impossible, please notate in the documentation that an alternative measurement was taken, and make sure to duplicate this technique for continuity as treatment goes on.



Radial and Ulnar Deviation: Wrist radial and ulnar deviation is also measured with the stationary arm along the middle of the distal forearm, and the movement arm directly dorsal to the third metacarpal bone, with the axis directly over the capitate bone (proximal to the base of the third metacarpal.) Hold the stationary arm in place, and hold the movement arm directly over the third metacarpal by bracing the goniometer at the MP joint. The patient’s hand is laid flat on the table, and the patient is instructed to make a “windshield wiper” motion with the hand, stopping at each end for the measurement. It is common for patients to naturally start with their hand in slight ulnar deviation, so making sure that they perform

the windshield wiper motion a few times prior to measuring is a good idea.



Pronation and Supination: Pronation and supination are easiest measured in a standing position. The ASHT recommends that pronation and supination are measured at the distal radius (as opposed to having the patient hold a pencil in their hand and measuring the movement of the pencil). With the shoulder adducted, elbow at ninety degrees, and forearm in neutral, the stationary arm of the goniometer should be aligned with the humerus, and the movement arm is placed either dorsal (for measuring pronation) or volar (for measuring supination). Make sure that the patient does not compensate by leaning to either side, or by abducting the arm away from the body.

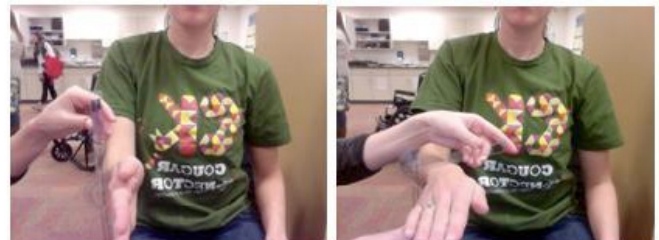

Figure a

Figure b

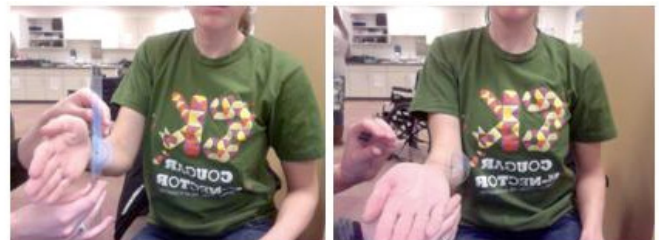
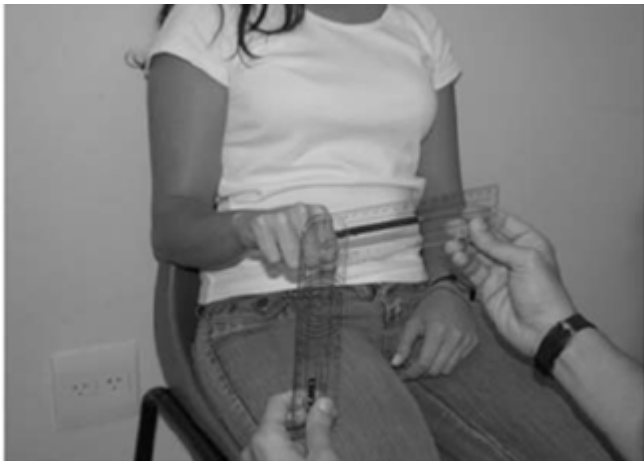
Figure a

Figure b

An alternative way to measure pronation and supination is by handing the patient a pencil in a closed fist, and dropping the stationary arm of the goniometer perpendicular to the floor (as shown), and aligning the moving arm with the pencil. The axis of the goniometer is the same as with the standard measuring protocol as described above. This is an acceptable alternate measurement according to the ASHT, although the therapist should be careful to not allow the patient to compensate with wrist motion when they have obvious forearm tightness. Since the wrist is very ligamentous, it can allow almost 15-20 degrees of accessory pronation or supination compared to a measurement taken at the end of the radius.

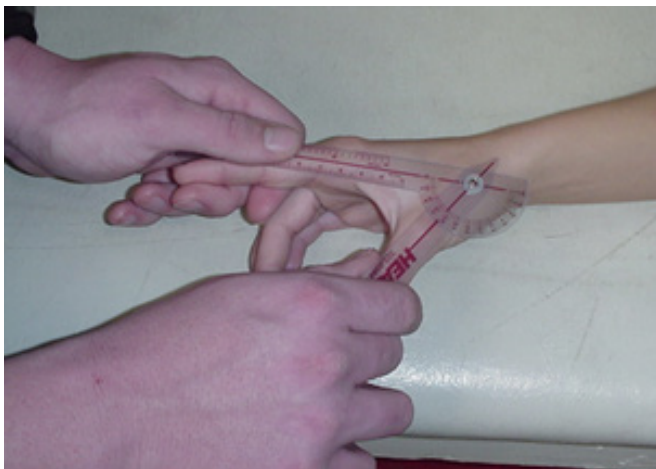


the second metacarpal. The axis of the goniometer is placed just proximal to the first metacarpal angle of separation between the two carpal bones. Hold the goniometer on the thumb MP joint and index finger MP joint. Ask the patient to abduct the thumb away from the hand as shown in the picture below. "Slide the thumb on the table away from the hand." Make sure to measure the angle of the two metacarpal bones (amount of angle from MP joint to MP joint), NOT the measurement of abduction to the IP joint of the thumb, as this will give you a false measurement. Most people have about 30-40 degrees of radial abduction. Compare to the other hand.



Thumb Abduction and Adduction: Adequate thumb abduction is needed for cylindrical grasp and is important to evaluate and monitor. Thumb palmar abduction (or thumb volar abduction) is a measurement of the motion at the CMC joint of the thumb. The stationary arm is placed along the first metacarpal bone, and the movement arm is placed along the second metacarpal. The axis of the goniometer is placed just proximal to the first metacarpal at the angle of separation of the two metacarpal bones. Hold the goniometer on the thumb MP joint and index finger MP joint. Ask the patient to abduct the thumb away from the palm as shown in the picture below. Make sure to measure the angle of the two metacarpal bones (amount of angle from MP joint to MP joint), NOT the measurement of abduction to the IP joint of the thumb, as this will give you a false measurement. Most people have about 30-45 degrees of volar abduction. Compare to the other hand.

Thumb adduction is measured in the same manner as abduction, with the stationary arm of the goniometer placed along the first metacarpal bone, and the movement arm placed along the second metacarpal. The axis of the goniometer is placed just proximal to the first metacarpal at the angle of separation between the two metacarpal bones. Hold the goniometer on the thumb MP joint and index finger MP joint. Ask the patient to "pull the thumb in as close to the hand as possible," touching the proximal phalanx of the thumb to the side of the index finger in the web space. Thumb adduction can be measured in the palmar plane and in the radial plane as needed (in conjunction with palmar abduction and radial abduction).

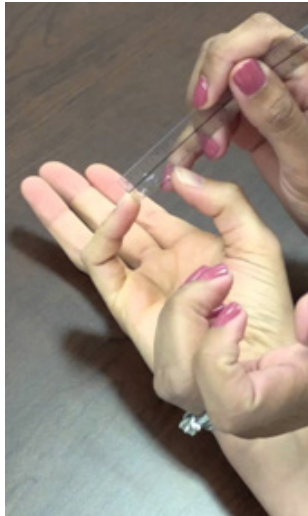

Thumb radial abduction is a measurement of the motion at the CMC joint of the thumb as the thumb is abducted away from the radial aspect of the hand. Place the patient's hand palm-side down on the table. The stationary arm of the goniometer is placed along the first metacarpal bone, and the movement arm is placed along

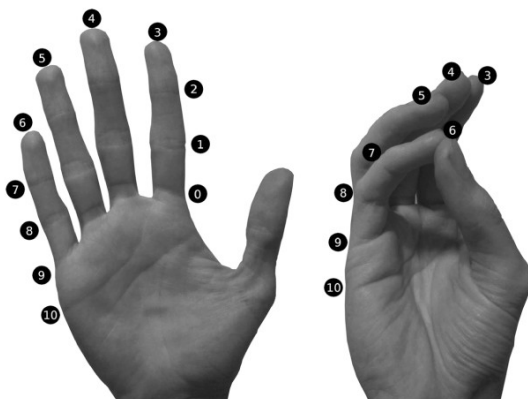
Thumb Flexion and Extension: Thumb flexion and extension are the measurements of motion of the IP and MP joints of the thumb. These are not commonly involved or affected with wrist fractures, but may be measured as part of a comprehensive evaluation if excessive stiffness is noted throughout the hand. Adequate MP and IP joint motion is even more necessary to assist in opposition and functional fine motor tasks if CMC joint motion is limited (due to wrist stiffness, pain, or any other factor). Thumb MP and IP flexion is measured over the dorsal aspect of the thumb using a flat, silver goniometer (when available) or laterally using a modified 6-inch plastic goniometer. Thumb IP hyperextension can be measured over the volar surface of the thumb. Compare these measurements to the unaffected side.

Opposition: Opposition has long been evaluated by asking the patient to oppose the tip of the thumb in attempt to touch the distal palmar crease at the base of the small

finger. The ASHT Clinical Assessment Recommendations 3E recommends using the ruler at the end of the plastic goniometer to attain a linear measurement of the distance between the distal palmar crease of the fifth digit and the distal nail fold of the thumb. An alternative linear measurement can be taken from the distal palmar crease to the distal palmar crease of the thumb during attempted active opposition.



Functionally, opposition can also be measured using a modified Kapandji Index as is used for patients with osteoarthritis. Thumb opposition is scored from zero to ten based on the thumb touching specific landmarks on the hand and fingers. If the patient is unable to touch any part of the radial aspect of the hand, the score is zero, 1) the thumb tip can touch the PIP fold of the index finger, 2) the DIP fold of the index finger, 3) tip of index finger, 4) tip of middle finger, 5) tip of ring finger, 6) tip of small finger, 7) DIP fold of the small finger, 8) PIP fold of the small finger, 9) MP crease of the small finger, and 10) the distal palmar crease at the base of the small finger.



The modified Kapandji Index is a quick and easy tool to use to assess opposition as opposed to gathering multiple measurements. This can be beneficial in patients with high anxiety or severe pain, or simply due to time constraints. A therapist only has so many minutes to work with a patient, and time spent measuring motion may be

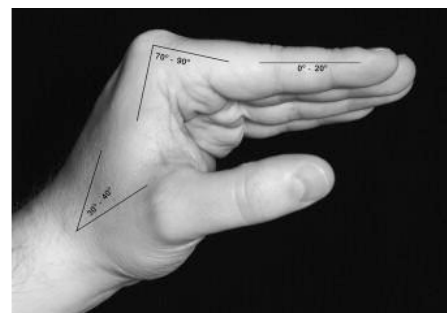
better spent teaching patients specific exercises to regain their motion and function. Also, when discussing and writing goals with your patient, it is wise to find out what types of activities they engage in and what type of hand motion that requires (specifically in your older patients with other co-morbidities that may result in long-term stiffness). Functionally, most activities do not require more than opposing to the tip of the middle finger, which is a four on the Index. So, although we would like to see all patients regain 10/10 opposition, keep in mind that a four is considered a functional amount of opposition for most activities.

Finger Flexion/Extension: Just as with thumb flexion and extension, finger flexion and extension only need to be measured when there is noted finger stiffness after distal radius fracture. Fingers can have extrinsic and intrinsic tightness following external fixation or any type of immobilization, so measuring finger flexion and extension may be necessary.

Passive Range of Motion and Joint Integrity: All joints can be measured for active range of motion as described above and for passive range of motion (PROM) in the same manner. The significance of measuring AROM vs. PROM is to assess each joint's integrity. This can assist the therapist in evaluating the potential for return of motion following injury or prolonged casting.

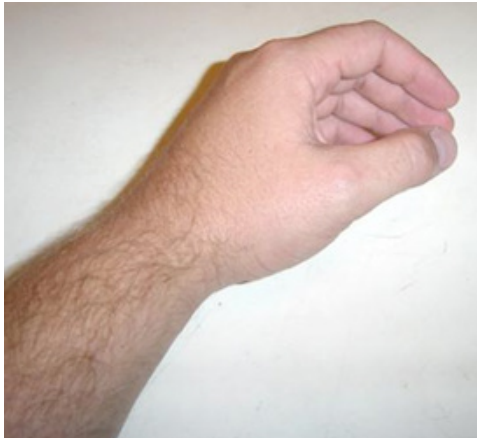The typical stiffness pattern for patients who have been immobilized with casting is moderate to severe MCP tightness, mild to moderate PIP tightness, and very slight DIP tightness. This is directly related to casting that extends beyond the distal palmar crease, not allowing adequate MCP flexion. To make matters worse, patients are afraid to use their hands or purposefully move their digits while in casting, even when the fingers are free, which naturally leads to decreased flexion.

All joints have a “close-packed” position and a “loose-packed” position, which refers to the position of the joint at rest. The joints will rest in certain positions due to the ligamentous stability and the joint capsule surrounding it. “Close-packed” positions are the position of most stability with the most joint congruity because the ligaments and joint capsule are on full stretch, essentially tightening around the joint. “Loose-packed” position provides the most play in the joint, as the ligaments (and capsule) are in their most relaxed or slacked position.



“Close-packed” joints

The loose-packed position is the “resting hand position.” Relax your hand. Observe the angle of your finger joints and the position of your thumb. Your hand will naturally relax into a loose-packed position at all joints. In general, the hand rests with the MP joints in a neutral position of (almost) full extension, and the IP joints rest in slight flexion. The thumb sits in a neutral position between flexion and extension, with the MP in extension and the thumb IP in slight flexion. Understanding and observing “normal” resting hand position is the basis for understanding and effectively treating deformity (or potential deformity). It should also be noted that the PIP joint has a thickening on the volar aspect, referred to as the volar plate. When the PIP is allowed to sit in a loose-packed position for a prolonged period of time (due to pain avoidance, stiffness, or swelling), the volar plate is also in a slightly contracted position. If not addressed, the volar plate can contract, causing extensor lag in the PIP joint.



The CMC joint of the thumb is “close-packed” in full opposition, meaning that in a position of opposition, the CMC joint ligaments are on their fullest stretch, which tightens up the joint and does not allow for accessory motion at the CMC joint. Full opposition allows for the most joint congruency at the CMC joint. The “loose-packed” position for the CMC is midway between flexion and extension. This position allows for the most amount of “joint play” because the surrounding ligaments are on slack.

The “close-packed” position for both the PIP and DIP joints of the fingers is full extension. The “loose-packed” position for the DIP is 10 degrees of flexion, and for the PIP is 30-35 degrees of flexion. This is important to note as it will become useful during the therapist’s evaluation of the affected joints. This also helps the therapist decide the best position to place the patient during manual joint mobilizations or conversely when immobilizing or supporting with splinting.

Digits that have been sitting in a prolonged “rest” will default to a close-packed position, meaning the MCP joints will be neutral, the PIP joints will sit in about 15-20 degrees of flexion, and the DIP joints will sit in about 10 degrees of flexion. Patients who have been immobilized with external fixation can develop tightness in a close-

packed position due to non-use of the hand from fear of dislodging the fixator or pain and swelling from the injury. Depending on the severity of the fracture, or if there are multiple fractures besides the distal radius fracture, some or all fingers can be affected by fixation. Occasionally a fixator may run close to a tendon, not allowing full excursion of the tendon even if the patient is not experiencing pain. Unless a patient is educated to actively flex and extend their fingers within the confines of the cast, they could potentially develop contractures at these joints. Even patients who are diligent with AROM of their fingers can develop MP tightness if their cast extends beyond the distal palmar crease.

Extrinsic and Intrinsic Tightness: Patients should be evaluated for extrinsic and intrinsic tightness so that their stiffness can be treated appropriately (treatment will be discussed in more detail later in the course).

The patient can be assessed for intrinsic tightness using the Bunnell-Littler test. Place the patient’s MCP joint in slight hyperextension and passively flex her PIP joint. Measure the PROM of her PIP joints of the hand. Then passively flex the MCP joint and re-measure her PROM of the PIP joint of the same finger. If the patient has more tightness with a hook fist than with a full fist, she has intrinsic tightness and should be treated accordingly. If the patient has similar tightness in the PIP joint regardless of the position on the MCP, it can be assumed that she has true capsular tightness in the PIP joint. With distal radius fractures, most patients will present with similar tightness in all fingers (as opposed to one outlying finger with tightness), but this is not always the case.



Patients will commonly develop extrinsic tightness from all types of immobilization including static splinting. Extrinsic tightness is caused by soft tissue restrictions to the extensor digitorum communis (EDC). The EDC can become adhered to underlying tissue with immobilization, but the muscle belly can also become tight and irritated with prolonged immobilization such as with a distal radius fracture. To check for extrinsic tightness, compare a patient’s full fist combined with wrist flexion of the affected hand to the non-affected hand. If the patient has a decreased fist in the affected hand with the wrist flexed, but has full excursion with the wrist in extension, you can assume that the EDC is either adhered or the muscle belly is restricted in some way.

Patients can have extrinsic tightness of the flexor wad as well, which will make full extension difficult. To check for flexor tightness, compare the patient's fully extended wrist and fingers of the affected hand to the non-affected hand. If the patient has decreased finger extension with full wrist extension (compared to the amount of finger extension he has with the wrist is neutral or in slight flexion), you can assume that the extrinsic flexors, the flexor digitorum profundus and flexor digitorum superficialis are either adhered or restricted in some way.

Amy's note: Sudden changes in extrinsic flexor tightness can be the result of a flexor tendon getting caught up on a volar locking plate after surgery. This is of concern because if the tendon is rubbing on the volar locking plate, it has an increased risk of rupture. If you notice during the course of rehabilitation that there is a sudden and obvious change in extrinsic tightness, contact the patient's surgeon.

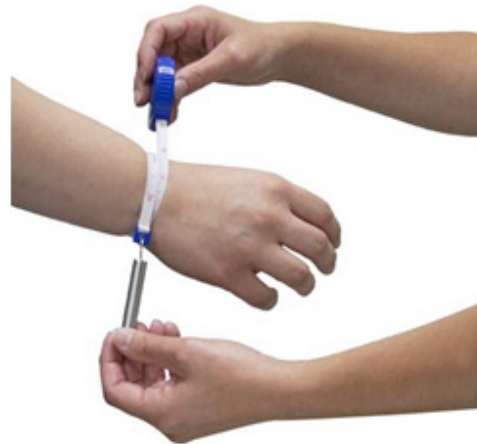Total Active Motion and/or Total Passive Motion: Total active motion is a composite number achieved by adding one digit's MCP flexion+PIP flexion+DIP flexion and subtracting any extensor lag to arrive at one number to report to your physician. It is important that the patient's wrist is in neutral when taking this measurement, and that the examiner cues the patient to start with their fingers in full extension (neutral) and then proceed to "make the best fist you can make." A common mistake made by therapists when measuring multiple joints in one finger is to measure the MP flexion with the patient fist, and then have the patient make a hook fist so that measuring the smaller joints is easier. This can result in false measurements, as it will not accommodate for extrinsic tightness and will not give the physician or payer source an accurate "picture" of the hand.



Edema: Although edema can only be measured completely reliably using a volumeter, these are not commonly found in clinics as they are bulky and messy. Most therapists do well with flexible tape measures, measuring circumference of the various tissues. The basic landmark measurements can be taken from the wrist, just distal to the ulnar

styloid, the circumference of the hand at the level of the metacarpal joints, and then each finger individually as necessary. If all digits are edematous, a representative circumference can be taken from the proximal phalanx of the middle finger. All measurements should be compared to the unaffected side, as there is no normative data available for edema. The most valuable data comes from comparing the patient's edematous hand to the unaffected hand, and also measuring edema from visit to visit for comparison.

Commercial tape measures are readily available and can be reused after wiped down with an alcohol swab. If infection is a concern, one-time use tape measures are available through the major rehab supplier catalogs.




Median Nerve Gliding: Although a median nerve gliding series is technically not a measure of active range of motion, it can be assessed during the AROM portion of the evaluation to assess any nerve irritation. Instruct your patient to complete a median nerve gliding series by mirroring your movements, holding each position for five seconds. They are to report any changes in sensation they experience, and the therapist can document this in the evaluation. The therapist typically will document the complaints with a combination of the patient's subjective report and the objective positioning of the patient. For example, "the patient complains of a shooting sensation in middle of the wrist when moving from position two to three in median nerve gliding sequence."

Amy's note: Oftentimes, the patient won't complain of a pain per se, but will note a "discomfort" in the hand with the series. Although this is not documented in the literature and is very subjective in nature, I watch the patient for any facial expression changes as they go through the series, because you will often see them close one eye or slightly grimace at the same point in the series each time. I use this as an indicator that the nerve is slightly irritated and note it as such. During treatment, as your patient becomes more adept at performing nerve glides, the pain or discomfort should reduce or move to a later part of the sequence (such as between positions five and six), and you can notate that the symptoms are improving.

Fine Motor Coordination: Fine motor activities should be assessed and added to the program as soon as the patient is cleared for active range of motion. Not only will this help the patient regain some finger motion, but it will reduce the likelihood of compensatory patterns, reduce soft tissue adhesions, and encourage the patient to engage the hand in activity as soon as possible. Non-standardized testing can be performed using any small items such as loose change, nuts and bolts, or small blocks, but standardized testing is recommended in order to compare to normative data and ensure test-retest reliability.

For baseline measurement of fine motor control, the therapist can use a standardized test such as a nine-hole peg test, Purdue pegboard, Jebsen-Taylor Hand Function Test, or the Minnesota Manual Dexterity test. Each of these tests have been studied and found to have adequate statistical validity and inter-rater reliability. In order to benefit from the normative data, the therapist must be sure to follow the standardized testing procedures closely. Each test comes with instructions, but most can also be found now online by typing the name of the test into a search engine. Standardized tests are a good way to measure progress as well because the data is objective. Sometimes this can be motivating to a patient, as they have difficulty seeing how much improvement they've made over the span of treatment.

Nine-hole peg test: Therapists have been using the nine-hole peg test since 1971, and it is still the simplest and most well-known dexterity test used in clinics today. Inter-rater reliability of the nine-hole peg test is very high; test-retest reliability of two back-to-back tests is fairly low, but can be accounted for by the practice effect. Research suggests that test-retest reliability actually improves with multiple tests or three or more. Studies also note that the normative data established by Mathiowetz, Weber, Kashman, and Volland in their main study in 1985 continues to be reliable for all commercially available nine-hole peg boards (Grice, Vogel, Le, Mithcel, Muniz, Vollmer, 2003).



The nine-hole peg test is an excellent tool to assess finger dexterity as a baseline when patients are approved to begin active range of motion. It is a preferred test because it is fast, easy to administer, and does not require prolonged use of a hand that may have very poor endurance due to pain and prolonged casting. The other standardized assessments of finger dexterity listed here tend to take longer, and may not be appropriate in the early stages of treatment.

Patients are tested on how quickly they can pick up nine pegs, one at a time, and place them in separate holes, and then remove them one at a time and place them back into the dish. The dominant hand is tested first, followed by the non-dominant hand. The test is invalid if the patient drops a peg on the floor or is interrupted in any way, and a new test trial should be completed. The timer starts when the first peg is picked up and stops when the last peg is placed back in the dish. Precise instructions are

given to the patient prior to the trial. These instructions come with the kit (or can be extracted from the internet), and must be given as written in order to accurately compare the patient's results to the normative data. Normative data is divided between male and female subjects, and is broken down into five year age ranges from ages 20-75+. In general, people between the ages of 20-75 can typically finish the test in 16-20 seconds.

Purdue pegboard: The Purdue pegboard can be used to measure fine motor coordination in one hand or in both hands simultaneously. The test is a board that consists of two parallel rows of 25 holes each. The test consists of four sub-tests, where the patient places small metal components (pins, collars, and washers) in the holes in a specific assembly pattern. The dominant hand is tested first, then the non-dominant hand, then both hands together, and then an assembly test is completed. Each sub-test takes about 30-60 seconds. Test score reliability increases if more than one trial of the tests is completed. To perform an entire test using three trials of each sub-test will take the therapist about 10-15 minutes, as the therapist is required to show the patient the testing procedure prior to testing. Normative data is available on subjects aged 5-89 years.



Lafayette Instrument Company has developed an app called Purdue Pegboard Scoring for iPhone and Android. It allows the therapist to administer the testing through the appropriate procedure while it keeps track of the patient's individualized data. It is free to download, but has in-app purchases if you would like to add organizational data for multiple patients. Normative data and associated research is also available.

Jebsen-Taylor Hand Function Test (JHFT): The JHFT is a functional hand assessment that evaluates a patient's ability to perform common functional tasks after injury or surgery. This test has been deemed a reliable test by industry standards; however, its validity in measuring hand function is questionable despite its widespread use. In other words, a patient's score may or may not measure a patient's ability to perform typical activities of daily living. Despite this fact, the Jebsen is well-received by patients, and continues to be considered a recognized

outcome tool for measuring hand function by third-party payers.



The original version of the test was developed in 1969 and has seven activities, but a modified JHFT was approved for use in 2004, using three activities. Due to the impact of distal radius fractures on all aspects of hand function, this therapist recommends using the original version of the test, as it assesses fine motor skills, weighted functional tasks, and non-weighted functional tasks. The modified version assesses fine motor skills only.

The full JHFT consists of seven subtests:

- Writing a short sentence (24 letters, 3rd grade reading difficulty)
- Turning over a 3x5 inch card
- Picking up small common objects
- Simulated feeding
- Stacking checkers
- Picking up large light cans
- Picking up large heavy cans

Specific guidelines for administering the test can be found online, but do not require any specialized training or authorization. The reader can also find the normative data in the original Jebsen article, which is readily available online as well. The test assesses speed only, not quality of performance. All items except for the writing subtest can typically be completed by a non-injured person in under 10 seconds. The entire assessment takes between 15-45 minutes to administer (Jebsen, 1969).

Although the kit can be purchased online, the norms can still be used if the therapist instead gathers all appropriate items for the test:

- 4 sheets of unruled white paper & clipboard
- Sentences typed in upper case centered on a 5x8" index card on a bookstand
- 5 index cards (ruled on one side only)
- Empty 1 pound coffee can
- 2 paper clips
- 2 regular sized bottle caps

- 2 U.S. pennies
- 5 kidney beans (~5/8" long)
- 1 regular teaspoon
- Wooden board (41 1/2" long, 11 1/4" wide, 3/4" thick)
- 4 standard size (1 1/4" diameter) red wooden checkers
- 5 No. 303 cans

Minnesota Manual Dexterity Test (MMDT): The MMDT is a standardized test for assessing the gross motor movement of the upper extremity and hand-eye coordination (as opposed to the other tests that measure just fine motor coordination). The MMDT was developed by the American Guidance Service in 1969 and is still in use today across the therapy field. The revised edition (1998) is currently available through Lafayette Instrument Company.



There are two ways to administer the test: either placing the disks from above the board into the board, or turning the discs over in the board. The therapist can also add displacing, 1-hand turning and placing, and 2-hand turning and placing as assessment options. Several trials can be performed at the discretion of the therapist. This test is easy to administer, but can be quite time consuming if several test batteries are completed. Normative data for the MMDT is not considered "critical," and should be used with caution: in other words, it is prudent to assess a patient's performance against his own trials in addition to comparing them to the normative data provided. Either way, it is important that the arrangement of materials (disks and board) and testing procedures follow the suggested protocol (Surrey, et al, 2003).

In addition to its assessment function, this test can be used as a treatment method to re-engage the affected UE in activity and normal movement patterns.

Grip and Pinch Strength: The expected timeline for beginning a strengthening protocol can vary from 6-12 weeks, depending on the stability of the healing fracture. Gripping causes stress to the wrist, so a therapist must never begin a strengthening phase without expressed consent from the treating physician; it should also be emphasized to the patient that they should not be gripping or lifting prior to getting consent from both their

physician and therapist. During the first six weeks after their surgery, patients with external fixation are limited to less than 31 pounds of grip and patients with internal fixation are limited to less than 36 pounds of grip in order to allow adequate healing to take place (Cooper, 2014).

Once strengthening has been approved, the therapist should obtain a baseline grip and pinch value for the affected and non-affected hand. When performing isometric testing for the first time, encourage the patient to achieve her best score without causing the hand/wrist any pain. Use clinical judgment: the value is only beneficial if the patient doesn't harm herself and cause increased swelling and pain response to the affected arm. Using a dynamometer, test the patient's grip and pinch in normal fashion: seated with arm adducted comfortably to the side, elbow at 90 degrees, forearm and wrist in neutral.

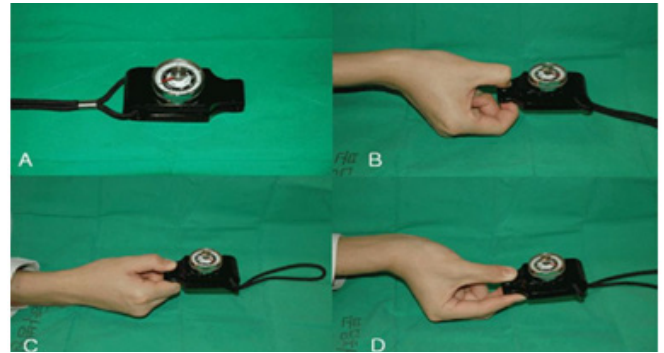
Grip Test: A standard grip test is three trials on the second handle-width setting. Any variations from this position should be noted in the patient's chart. Compare to the unaffected side. Document any complaints related to testing such as a sharp pain, difficulty with grasp, or inability to hold the testing equipment comfortably. The average of the three trials is the calculated score to compare to normative data, which can be found online and in many textbooks, but should be used with caution.



Amy's note: Experienced therapists have found that although "averages" for grip strength are reported at a certain level, this does not mean that a person needs the reported average grip strength for functional use of the hand. Functionally comparing the grip strength of the affected hand to the unaffected hand is much more valuable information for any one particular patient.

Pinch Test: The three positions for testing pinch strength are lateral pinch, three-point pinch, and two-point pinch. The lateral pinch is between the radial side of the index finger and the thumb. The three-point pinch (or three jaw chuck pinch) is between the thumb and the pulp of the index and middle fingers – instruct the patient to place the ring and small fingers in a full fist to avoid compensation. The two-point pinch (or tip to tip pinch) is between the thumb and the pulp of the index finger – instruct the patient to place all other fingers in

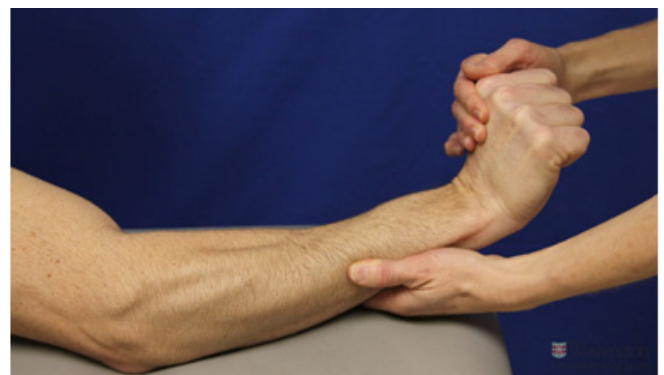a full fist to avoid compensation. Each test should be performed with three trials. The average of three trials is the calculated score to compare to normative data.



After both tests, discuss the results in relation to the patient's ADLs, job duties, and recreational goals. Most daily activities require about 20 pounds of grip strength and 5-7 pounds of pinch strength. This information can be helpful in encouraging and motivating patients to perform their exercises in order to regain the minimum strength required to conduct activities independently (Smaby, et al., 2004).

Wrist and Forearm Strength: In addition to grip and pinch strength, wrist and forearm strength can be evaluated at the initiation of strength training, as well as throughout the remainder of the treatment. Manual muscle testing can be used to assess strength using the Trace to Normal scale (below) or the numeral manual muscle testing scale. The elbow and shoulder strength can be evaluated as well.

- 1 Trace
- 2 Poor
- 3 Fair
- 4 Good
- 5 Normal



Treatment

After completing a full evaluation, the therapist can establish the treatment plan – taking into consideration the type of medical intervention that has been administered by the physician, the number of weeks post-injury, and any other considerations that we have

discussed. First, we'll look at typical timelines for rehab – these can be used as a reference to inform treatment. After that, we'll discuss special considerations for treatment modalities – these can help the therapist establish a customized plan for their patients.

Rehabilitation Guidelines for Common Distal Radius Fracture Interventions

Cast: Cast is usually applied for 4-6 weeks, then patient progresses to static orthosis for 2-4 weeks for comfort

- Pain control at initial evaluation
- Edema control at initial evaluation (positioning, retrograde massage, AROM of uninvolved joints)
- Wean from protective splinting as able
- AROM begins at MD approval when cast is removed. Begin light ADL activities without resistance and monitor movement patterns, add nerve gliding as needed.
- Static progressive splinting to address joint contractures or soft tissue restrictions after 6 weeks
- Progress to strengthening, weight bearing, and proprioception training at 12 weeks or sooner with MD approval

External Fixation: Hardware is usually in place for 4-8 weeks depending on severity

- Pain control at initial evaluation
- Edema control at initial evaluation (positioning, lymph massage, AROM of uninvolved joints)
- Pin site care at initial evaluation, wound care as needed
- Immediate AROM of uninvolved joints – check with MD to see if pronation/supination is appropriate
- Desensitization program as needed
- When hardware is removed, begin forearm and wrist AROM. Also begin light ADL activities without resistance and monitor movement patterns; add nerve gliding as needed
- Wean from protective splinting as able
- Add PROM as needed 2 weeks after AROM has been initiated if approved by MD
- Static progressive orthosis as needed to address joint contractures and/or soft tissue restrictions and regain ROM when approved by MD
- With MD approval, begin strengthening, weight bearing, and proprioception training

Internal Fixation:

- Pain control at initial evaluation
- Edema control at initial evaluation (positioning, retrograde massage, AROM of uninvolved joints)
- Scar management, wound care as needed

- Immediate AROM of uninvolved joints
- Wrist AROM begins at one week post-op with MD approval; also begin light ADL activities without resistance and monitor movement patterns
- Desensitization program to incision as needed
- Wean from protective splinting as able
- Add gentle PROM as needed 2 weeks after AROM has been initiated if approved by MD
- Static progressive orthosis as needed to address joint contractures and/or soft tissue restrictions and regain ROM (specifically wrist extension) when approved by MD
- With MD approval, begin strengthening, weight bearing, and proprioception training

Accelerated vs. Standard Rehabilitation Protocol

A randomized controlled study of 81 patients was performed between 2007-2010 (Brehmer & Husband, 2014), comparing an accelerated timeline for rehabilitation to a standard timeline for patients following volar plate fixation of unstable DRF. Both groups began with gentle AROM 3-5 days after surgery, but the accelerated group began wrist and forearm PROM and strengthening at about two weeks (compared to the standard group who started this at six weeks). Patients in the accelerated groups had better clinical and statistical mobility, strength, and functional outcome scores (using the DASH) than the standard group, suggesting that with physician approval, we may be able to begin PROM and strengthening much sooner than we originally thought was safe. Upon receiving this valuable update, hand therapists have begun employing an accelerated timeline of treatment with excellent clinical results. Although this is promising data, therapists must be very cautious in accelerating the protocol and should only do so with written or verbal approval from the treating physician.

Therapeutic Modalities

AROM/PROM of Proximal Joints: Although it is easy to overlook, the therapist should check frequently on the ROM and strength of the associated shoulder and elbow, as they can be adversely affected by immobilization. Oftentimes patients will use a sling immediately following injury, and almost always will guard their UE in some way during the immobilization phase. Naturally, if a person is not using their hand for function, they will posture the arm in an adducted position with the elbow flexed. If left unchecked, this can cause soft tissue tightness and shortening of the internal rotators of the shoulder and the flexors of the elbow.

Educate your patient to active shoulder abduction, external rotation, circumduction, and elbow extension three to four times per day to prevent any proximal joint complications. Patients who are instructed to “climb and swim” (pretend to be climbing a ladder, and do various swimming strokes) several times per day can avoid soft tissue tightness, and will also inadvertently reduce dependent edema. Proximal

motion can also stimulate lymph drainage and increase circulation which aids in healing.

If a patient arrives in the clinic at a later stage of healing and already has some proximal joint tightness, a more aggressive approach to active or passive motion may be necessary. In addition to AROM exercises, the patient may need anterior pectoral stretching (a doorway stretch), soft tissue mobilization to the anterior pectorals, shoulder PROM, and/or elbow PROM. Patients who have been guarding their upper extremity benefit from relaxing in a supine position during AROM and PROM exercises, as it decreases the postural guarding coming from the trunk. In cases of severe guarding, a patient may also benefit from supine deep breathing (or diaphragmatic breathing) techniques, as well as soft tissue mobilization to the thoracic and cervical spine, neck muscles, and shoulder girdle.

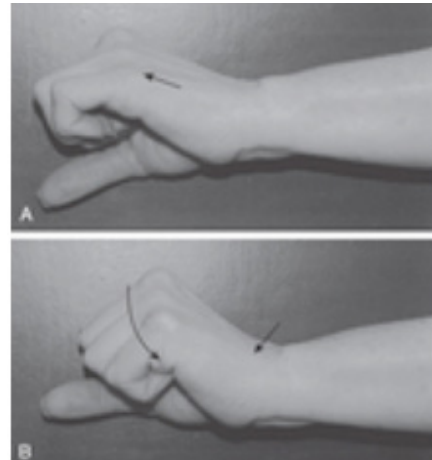
Amy's note: Never underestimate the power of good, old-fashioned TLC to reduce your patient's anxiety regarding treatment. When you address their concerns by giving them exercises that don't hurt, you gain their trust and compliance with treatment. Proximal shoulder ROM exercises are a great example of non-painful exercises that can be very beneficial.

The first eight weeks of healing are the “window of opportunity” for regaining the motion compromised by the injury. This is the phase of healing where collagen is being deposited but has not begun to mature. Patients must be educated to this in order to motivate them to participate in exercises that might be somewhat uncomfortable. Wrist and finger ROM may suffer permanent loss if not addressed appropriately.

AROM of Involved Joints: As reported earlier, active range of motion of the wrist and “involved” joints of the injury should begin, gently, following immobilization (with permission from the surgeon). Patients must perform intentional finger flexion, extension, and abduction/adduction. Thumb palmar and radial abduction, adduction, and opposition should be performed as well. And of course, wrist flexion, extension, radial deviation, ulnar deviation, and pronation and supination should be also be performed. All motions should be performed to a tolerable end range and held for a count of five, 10-15 times each, three to four times per day as part of a home exercise program.

It is more important to stress “intentional movement” – purposeful, planned movement – with the patient rather than number of repetitions, amount of time spent at end range, or number of exercise sessions per day. Although all of these factors are important, if the patient isn't reaching the end range of the joint during AROM exercises, they are losing the efficacy of the workout and will have suboptimal results. Without this guidance, patients will often “wiggle” the fingers, the report that they have been moving the fingers often but are still stiff. Wiggling the fingers doesn't stimulate lymph exchange or circulation, and is relatively useless in the grand scheme of hand rehabilitation.

Active range of motion is important, but can be done too aggressively, causing increased pain and swelling. Therapists should be careful to monitor a patient's subjective complaints before and after exercising. One modification to AROM exercises if they are causing irritation is exercising from neutral to end range 10-15 repetitions and then moving on to the next exercise. For example, when performing wrist AROM, have the patient exercise from neutral to extension 10-15 times, and then neutral to flexion 10-15 times, et cetera. This is less painful subjectively from the end range of extension to flexion, and back and forth. Patients tend to tolerate this modification very well.



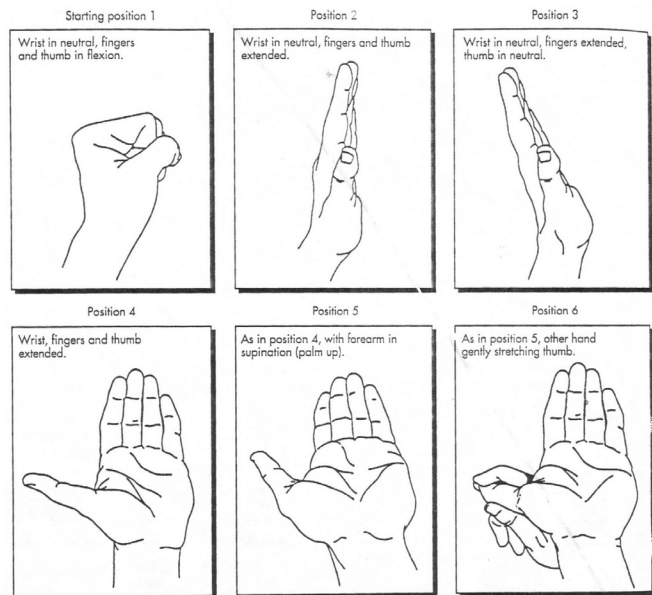
Amy's note: Another consideration for active wrist motion exercises is eliminating any compensation for wrist extension by using the extensor digitorum communis, or finger extensors. In this substitution the patient will have noted MP extension when attempting to actively extend the wrist. A good way to avoid this pattern is to educate the patient to the substitution and to have the patient hold a marker or a dowel, making sure that the fingers are still and not providing any active motion. Patients will feel slightly less comfortable performing the exercise correctly because the wrist extensors are deep to the finger extensors and may have more adhesions to the injury site. Monitor for this pattern often, as patients may develop it over a period of several weeks.

Active range of motion exercises should progress as time goes on, and patient expectations as well as physician expectations should be addressed. Discuss your patient's activities of daily living to determine how much motion is necessary for their “return to normal.” Be aware that bony alignment may not be optimal, resulting in long term motion deficits: if you feel you are not making adequate gains in active motion, consult with the physician about his expectations, and adjust your treatment accordingly.

Median Nerve Gliding Treatment: Patients should be instructed to go in order during a median nerve gliding series, hold each position for five seconds, and DO NOT progress to the next step if symptoms are present. When a patient feels nerve irritation during the series, they are to stop the progression and go back to step one in the series. A patient (and therapist) will know they are making

progress with the nerve gliding exercises when they can move on to the next step without nerve irritation or pain. Patients who overdo their nerve gliding exercises will end up with more pain, so this cannot be stressed enough when educating a patient.

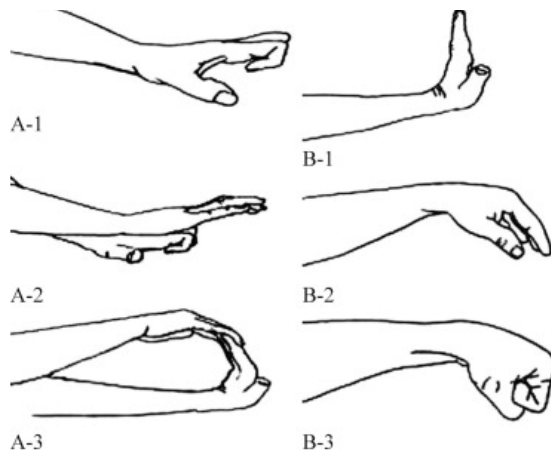
Please see the most common median nerve gliding series noted below, as described by Mackin and Callahan in 1991:



Amy's note: A median nerve gliding program should be added to the patient's home program, whether or not the patient is displaying symptoms, in order to avoid this common complication. A frequency of ten repetitions three times per day should be adequate in addressing mild symptoms of nerve compression. Make sure to stress that moving "past the point of discomfort" is not necessary and can be more damaging to the nerve.

Lumbrical stretches may also help alleviate median nerve irritation in patients with an onset of numbness during the rehabilitation phases for distal radius fractures. The directions for lumbrical stretching are as follows:

- Rest the hand on the thigh with PIP and DIP joints fully flexed
- Press the hand down on the thigh with the other hand to provide a "stretch" over the MP joints
- Passively stretch fingers and wrist into maximally tolerated extension
- Actively hold this position for five seconds
- Take a five second rest
- Make a fist and actively flex the wrist to maximally tolerated flexion. (Baker et al, 2012).

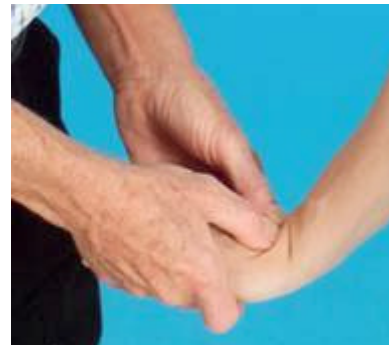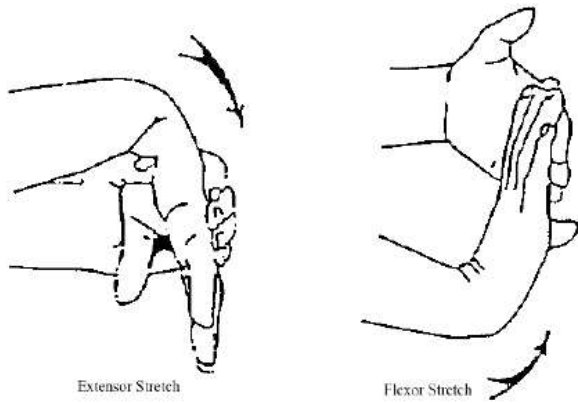


Passive Range of Motion: Although passive range of motion can be examined on the initial evaluation to assess joint integrity, passive range of motion exercises are typically initiated two weeks after patients have been performing active range of motion exercises – as long as the patient is not having increased pain, and assuming the patient continues to have residual tightness in the hand or wrist. Passive range of motion is NOT indicated if the patient has no motion restrictions, as this may indicate that the patient is not building a lot of scar tissue or that she has no soft tissue restrictions. Therapists do not need to add PROM simply because it is written in the protocol. It should only be used when necessary.

Passive range of motion can be used for musculotendinous tightness, as well as for actual joint capsular tightness. The techniques for addressing these types of tightness are different, and must be treated accordingly. It is important for the therapist to identify what type of tightness is occurring in order to treat it effectively, and to educate the patient in the same regard.

Joint Tightness: Actual joint tightness means that the PROM of the joint the therapist is assessing DOES NOT CHANGE with movement of an adjacent joint. For example, if the patient has decreased PROM of the middle finger PIP joint whether or not the MP joint is flexed or extended, then the actual capsule of the PIP joint is stiff. This type of stiffness is addressed by passively stretching the PIP joint in any position, and providing manual joint mobilization to the PIP joint. Dynamic splinting or static progressive splinting to the actual joint will be helpful in reducing this type of stiffness.

The same techniques can be used for the wrist complex. If the actual wrist joint is stiff compared to the unaffected side, the therapist should educate the patient to passive range of motion exercises. Custom or prefabricated dynamic splinting can be employed, as well as static progressive splinting to address any specific ROM deficits. It is important to note that the only joint that should be placed on a stretch should be the joint that is stiff. If the therapist inadvertently stretches the surrounding healthy (non-stiff) joints, she is putting undue pressure on them and can damage their integrity.

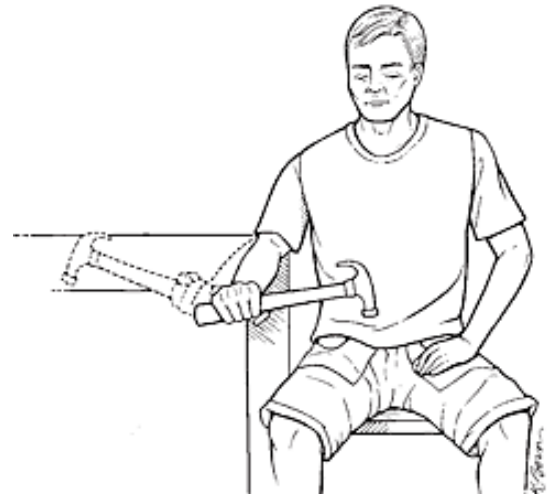

Amy's note: The lunate is located just proximal to the base of the third metacarpal. Provide a small amount of counterpressure over the dorsal aspect of the lunate when performing wrist extension, and provide the same amount of counterpressure over the volar surface of the lunate during flexion. Essentially, you are "getting the lunate out of the way of the movement." This is how I explain it to patients so that they can perform the same slight counter-pressure during their home program.

Passive range of motion for actual wrist tightness can be provided by the therapist to the patient, or patients can self-range using open-chained and close-chained techniques. Open chain PROM would include standard stretching of the wrist using the unaffected hand to place a passive stretch on the affected wrist. Close chained PROM would involve placing the hand on the edge of the table, holding it in place with the other hand, and moving the forearm to create wrist flexion, extension, ulnar and radial deviation. Weight bearing activities also provide a passive stretch into wrist extension in addition to providing proprioceptive feedback to the wrist and hand. PROM exercises should be initiated about 2-3 weeks after AROM exercises have been issued, and should be performed in the clinic and as part of the home program. The planes of motion that should be addressed are the same as with AROM: wrist flexion and extension, ulnar and radial deviation, pronation and supination, and dart-thrower's motion (radial extension and ulnar flexion). Patients should not have a significant increase in pain or swelling with PROM, otherwise it is much too aggressive. Therapists and patients should all understand that increasing edema is counterproductive to the overall goal of treatment. The body responds according to its own healing timeline, and this may vary from patient to patient.

Forearm pronation and supination are necessary for normal functional use of the hand and can be difficult to regain following a distal radius fracture. Again, making sure that stretching is occurring at the distal radio-ulnar joint is paramount, as compensation at the carpus can cause ligamentous damage, specifically to the ulnar aspect of the wrist. Instruct patients to perform PROM at the DRUJ, NOT by passively "twisting the hand" in pronation or supination. Another good way to avoid carpal stretching and to provide a lever arm to control the amount of pressure to the DRUJ is to use two pieces of splinting material and some slo-foam to fabricate a rectangular stretching device. You can add velcro or simply apply the orthosis to the volar and dorsal aspects of the DRUJ using an ace bandage so that the patient (or therapist) can appropriately apply the passive motion to the DRUJ while supporting the carpus.

A typical home program would be 10-15 repetitions, 3-4 times per day. Passive motion should be performed to a comfortable end range, and tissue response should be monitored. Likewise, when performing PROM to your patient, make sure to monitor their complaints of discomfort and pain. When there is swelling in the carpus, even carpalis with perfect ligament congruence can have trouble with smooth scapho-lunate articulation, causing pain in the S-L joint, or pain on the ulnar aspect of the wrist. This discomfort can be reduced by providing some external support to the lunate, assisting its glide into flexion when performing wrist extension, and assisting its glide into extension with wrist flexion.



Other therapists often use a hammer with a weighted end to provide a stretch, or twist a towel around the forearm

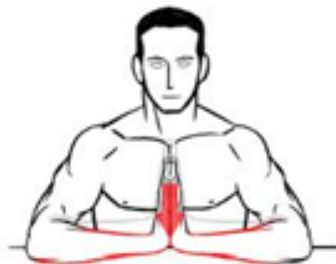in either direction (depending on pronation or supination), but I believe this can lead to ligament instability and ulnar sided wrist pain. If you use these techniques, use them with extreme caution. A good modification for these common techniques is to immobilize the wrist with either a custom or pre-fabricated wrist cock-up splint to maintain adequate wrist support while performing the exercises.

Musculotendinous Tightness: Musculotendinous tightness refers to joint tightness related to tissue outside the actual joint. A joint that is tight due to musculotendinous tightness will have varying degrees of PROM deficit according to changes in motion of the adjacent joints. Unlike joint tightness, musculotendinous tightness must be addressed by stretching more than one joint at a time.

Using our PIP example above, the therapist would note that the PIP joint has tightness that changes with manipulation of the MP joint. The Bunnel-Littler test will test for intrinsic tightness. Intrinsic tightness will result in less passive flexion of the PIP joint with the MP joint extended, and more PIP joint flexion with the MP flexed. The treatment for this is simple: if your patient has intrinsic tightness, place them in the “tight position,” which would be a hook fist, and stretch them in that position. Placing them in a full fist will not reduce intrinsic tightness.

Extrinsic tightness is tightness to the flexor or extensor wads, which are located on the volar and dorsal surface of the forearm respectively.

Extrinsic flexor tightness is very common with distal radius fracture, and presents as such: finger extension is compromised when the wrist is actively or passively extended. For example, the patient can actively extend the wrist to 45 degrees with the fingers in a tight fist around a dowel, but with the finger in full extension, the wrist can only extend to 25 degrees. If the patient is prompted to extend the wrist further, the fingers will flex due to the tightness. (Some finger flexion is normal as is seen with tenodesis; however, the patient should be able to perform the test equal to the unaffected hand.) Treatment for this is adding a “prayer stretch” to the patient’s clinic and home program, and performing soft tissue mobilizations and modalities to the flexor wad. Static progressive splinting can also be employed at night to regain full extension of the wrist and hand.



Amy's note: Extrinsic flexor tightness should be addressed, as weight bearing over the hand most commonly requires an open hand. Pushing a swinging door open, for example, requires an open hand and wrist extension. Playing catch with a baseball requires a moderate amount of wrist extension, with the fingers in a fair amount of extension in the glove.

Extrinsic extensor tightness is a less common problem functionally than its counterpart. Testing for extrinsic extensor tightness would be comparing wrist flexion with the fingers closed to wrist flexion with the fingers open. (Again, tenodesis does not allow for a tight fist at the end range of wrist flexion, but the affected wrist should be compared to the unaffected wrist to determine how much of a deficit is noted.) A simple treatment to address extrinsic extensor tightness is to wrap the patient’s fist with an ace bandage and work on active and passive wrist flexion. Soft tissue mobilizations and modalities to the extensor wad can also eliminate extensor tightness. Static progressive and or dynamic splinting is not recommended for extrinsic extensor tightness due to the provocative wrist flexion position that could irritate the median nerve.

Edema Control: Edema is the most underrated complication following a distal radius fracture. Patients may complain more of pain as their primary concern, but edema is the leading cause of poor outcomes, as it can “clog up” in the hand and create soft tissue adhesions. Without good motion in the wrist and fingers, it is very difficult to get full function back in the hand.

Inflammation is a normal response to injury, and is necessary to usher in the chemical protein properties responsible for fracture healing. The body’s natural response to injury is an influx of healing cells, including cytokines, histamines, prostaglandins, and fibrinogen, to increase stability and vascularity. This process takes from one to five days and the edema from it lasts about ten days. Over the next several weeks, the fibroblasts start to form a collagen network, creating interstitial scarring. This lasts around six weeks and is the time when regaining motion is most easily attained. At around the sixth week, the cells begin the maturation phase, which can continue for up to two years. Adhesions become increasingly resistant to change as time goes on” make sure your patient know this, and emphasize that compliance with AROM exercises in the early stages of treatment is important (Slutsky, 2005).

Amy's note: Regaining motion is easiest in the first six weeks of therapy. After that, the adhesions become increasingly resistant to change. Edema must be managed in this stage in order for patients to have the most optimal outcome.

Proximal edema control techniques can help stimulate lymphatic exchange, which will help reduce edema and improve tissue healing. Diaphragmatic breathing (breathe in and push the belly out, then breathe out while pushing the belly in), shoulder flexion, abduction, and circumduction, and scapular elevation, depression, protraction, and retraction will not only help keep the circulation and soft tissue healthy, but will help reduce

edema throughout the extremity.

Amy's note: Patients can easily incorporate these techniques into their daily routine, and should be encouraged to perform proximal edema control techniques at the beginning of each clinic session as well – this ensures that the patient is performing the exercise and stresses the importance of edema control as a crucial part of treatment. Proximal ROM and breathing exercises are usually received very well by patients, as they are not painful and give them a sense of achievement and progress with their program.

Generalized Soft Tissue Sequelae: Because the structures in the hand and wrist are compact and varied, soft tissue injury is commonly seen with distal radius fractures, and is often more problematic than the fracture itself. Tendon injury, nerve dysfunction, vascular compromise, ligament dysfunction, hypersensitivity, scarring, compartment syndrome, and complex regional pain syndrome are among the most common soft tissue injuries and complications associated with distal radius fracture. Some of these sequelae are due to the initial injury itself, but many can be a result of immobilization, surgical intervention, and the patient's history of healing. We will address the less debilitating ones here, and consider serious complications such as nerve compression and tendon injury in more depth later.

Wrist Tendinitis: Patients who complain of a sudden onset of thumb pain (or radial-sided wrist pain) should be evaluated for wrist tendinitis of the flexor carpi radialis. This is achieved by palpating the tendon insertion (volar base of the second and third metacarpals) while the patient is performing isometric wrist flexion. Point tenderness at the tendon insertion should be addressed accordingly, with modalities to reduce pain, cross-friction massage, soft tissue mobilization of the muscle belly, kinesiotaping to reduce muscle spasms and support the joint, and eventual return to strengthening. The flexor carpi radialis tendon is the most common tendon involved in tendinitis following distal radius fracture, but any wrist extensor or wrist flexor can be affected. If the patient has point tenderness anywhere on the wrist with isometric testing, these treatment techniques should be applied.

Nerve Dysfunction: If a nerve suffers damage from the initial injury, it may have to be surgically repaired, which requires modifying the treatment protocol to allow the nerve time to heal. Motion that would put the nerve on stretch will need to be avoided as per the surgeon's protocol. Nerve dysfunction is not a common complication with distal radius fractures; however, overall nerve irritation and compression are common, due to immobilization and chronic edema.

Hypersensitivity: Many patients complain of skin hypersensitivity after their cast has been removed, which can be distracting as they begin their rehabilitation. Although hypersensitivity is quite normal and often resolves on its own, the therapist can provide a desensitization program of sensory dowels (rubbing

different textures on the surface of the skin), particle immersion (such as beans, rice, cotton, balls), and vibration to the skin to re-educate the sensory endings and reduce the hyperactive ascending (pain) pathways to the brain.

Amy's note: Therapists should educate patients that the nerves in the skin receive active sensory input in everyday life due to normal use of the hand: the skin it is used to having clothing touch it, as well as everyday bumping and brushing, and it also receives input from its own movement. When a body part is injured and immobilized, the skin loses the normal input that it once received. If a nerve does not receive normal input, it sensitizes (or "turns up") in order to try to listen for input; then, when the cast is removed, the skin is suddenly bombarded with input again. Desensitization involves turning the nerve back down to its normal state.

Physical Agent Modalities

Physical agent modalities have been a complement to hands on treatment for many decades, and can be used both to prepare tissue for manual treatment and to calm it after aggressive exercise. Ensure that your physical agent modalities are approved by the treating physician before applying them to your patient.

Heat Modalities: Heat increases blood flow, and helps to increase the flexibility of tissues. Patients typically report temporary relief with heat treatments, and tend to tolerate exercise better following heat modalities. Heat modalities commonly used in the clinic are continuous ultrasound, moist heat packs, diathermy, and paraffin. Heat treatments involving energy waves such as ultrasound and diathermy should not be used on patients with internal fixation unless ordered by the physician. Ultrasound has long been considered contraindicated in the case of any metal implants, and its effect on fracture sites is controversial.

Cold Laser: Cold laser (low level laser therapy, or LLLT) also reduces pain in patients with soft tissue injuries and those who have undergone recent surgery. Cold laser is reported to reduce inflammation of surrounding tissue by stimulating ATP production to the area, thereby reducing pain. Essentially, the patient's body responds to the laser by sending stimulating ATP uptake, which helps the cells to heal more quickly. Minimal research has been completed on LLLT compared to other modalities, but patient satisfaction is very high.

Amy's note: Having used a cold laser for the last eight years, I believe it has completely changed my practice in that patients tolerate functional activity more quickly and report less pain. I was as skeptical as the rest before trying it, but can't imagine my practice without it anymore. I believe patients have less post-operative swelling, bruising, and pain with use of the cold laser three times per week. In addition to less pain with motion, most of my patients report a general sense of well-being after laser treatment.

Electrical Stimulation: Electrical stimulation can also temporarily relieve pain in some patients, although I've

found this is most helpful in patients that are having soft tissue complaints such as muscle spasms due to compensatory movements to avoid pain (at the joint). For this reason, when I use e-stim, it is typically to the flexor or extensor wad in the forearm to reduce muscle pain. I've found clinically that joint pain doesn't respond as readily to e-stim as muscle tissue does.

Moist Heat and Ice Treatments at Home: If patients report that they like moist heat better than ice, a common recommendation would be to purchase a paraffin unit for use at home. Home paraffin units are typically easy to find, particularly around the holidays: they are available at most discount stores (like Wal-Mart or Target), at pharmacies, at specialty stores (like Bed, Bath and Beyond), and at salon wholesale stores. If a patient is tech-savvy, paraffin units can be easily found online and shipped right to the patient's door. Patients typically use these in the morning after they get out of bed: moist heat tends to decrease stiffness from lack of motion at night, and prepares a patient for their daily routine. This is especially helpful for people who like to take their showers in the evening (people who take showers in the morning tend to get a nice moist heat from bathing).

Another simple alternative that is very popular with patients is to take a bath towel, wet it down, and place it in the microwave for about two minutes, checking on it every 30 seconds to see if it is warm enough. Patients can heat up the towel and place their hands in that moist heat for several minutes before it cools down. Wrapping the wet towel in a dry towel will also hold the heat in for a little bit longer (and keep the mess to a minimum).

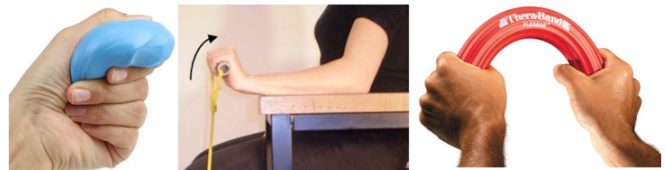Ice can be indicated as part of a home program following the patient's exercise program and after excess activity. As far as cold treatments are concerned, there are commercially available cold packs that are quite comfortable: Elastogel.com is an excellent source for a commercial cold pack; they can also be purchased on Amazon and other therapy websites. Patients who really enjoy cold as their treatment of choice may choose to invest in a gel pack – there are even mitt-shaped gel packs that will surround the hand with cold treatment. Otherwise, a bag of frozen peas works very well and is readily available; it's also a much cheaper treatment option since Elastogel packs cost somewhere between \$30 and \$50 each.



Strengthening

Strengthening of the wrist and hand can begin with physician approval around 8-12 weeks post-injury. All planes of motion should be addressed, just as they are with active and passive range of motion, and should include wrist flexion and extension, radial and ulnar deviation, pronation, supination, and dart-thrower's motion. Just as with PROM, monitor patient complaints as to not overwork the carpal ligaments and cause strain. Increased pain or swelling after strength training should cue the therapist to modify the treatment in some way. Strengthening can also be graded from mid-range strengthening to end-range strengthening, and is typically tolerated well.

Wrist strengthening can be performed with free weights, a weight-well, resisted bands, tubing, or putty, or any heavy functional activity that a therapist can dream up. A weighted hammer is often used to address several motions and can be graded from easy to hard by starting at the middle of the hammer with a light weight wrapped around the head and progressing to holding the end of the hammer with a heavier weight wrapped around the head. Strengthening the wrist is crucial to regaining the full strength of the hand. Although our natural tendency with regards to assessing strength is to rely on grip and pinch numbers, these will often be affected by lack of wrist strength as well as wrist instability. Therefore, make sure that wrist strengthening is part of the overall grip strength program that you develop.



Grip strength can be improved using theraputty or dynamic grippers, or even by doing functional activities such as wringing out a wet washcloth or squeezing a foam ball. Encourage your patient to perform grip strengthening exercises with all different angles of wrist extension and flexion in order to simulate functional activities. Single plane exercises are simple, but do not necessarily translate to functional activity.

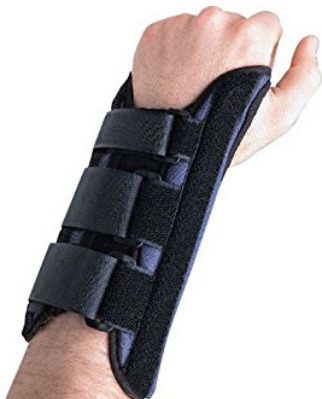Pinch strength can also be affected by distal radius fracture and long-term casting. Patients who are not using their hands functionally for several weeks will have overall atrophy to the fingers as well as the wrist. Pinch strength exercises include using putty, dynamic grippers, and rubber balls, as well as functional activities such as opening ziploc bags, removing a pen lid, pushing on a lotion bottle top, using nail clippers, or squeezing out toothpaste. Starting a car is also a very good activity to work on pinch and grip strength, wrist stability, and active supination.

Amy's note: Increasing grip strength seems to be one of the most important clinical factors that influence whether or not

a patient feels he has made adequate progress with therapy. Patients enjoy knowing what their numbers are on the dynamometer and pinch gauge and can become frustrated when they don't show improvements every week. It is not realistic to expect grip strength to improve dramatically from week to week, just as it would not be realistic to expect massive gains in any other muscle group from week to week. Encourage patients to try their best during testing, but educate them that grip testing will only be tested every three to four weeks to monitor for true change in strength.

Splinting for Immobilization and Mobilization

Orthotics are commonly used in the management of distal radius fractures for a variety of reasons. Initially, the patient may require wrist support following prolonged casting (and subsequent wrist weakness). In this case, the therapist should provide an orthosis that provides support and comfort to the patient, which may involve splinting the patient with a neutral or even slightly flexed wrist. This is common as patients are often casted in wrist flexion to allow proper alignment of the fracture.

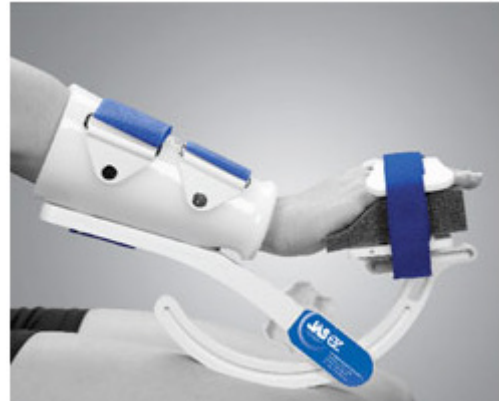

The accepted protocol for orthotic wear is between exercises and at night (Cannon, 2001).

The ultimate therapeutic goal is to sequentially adjust the orthosis into thirty to forty degrees of wrist extension in order to stretch the wrist soft tissue and allow for appropriate positioning of the hand for function (Coppard & Lohman, 2015). Ideally the patient will tolerate this amount of wrist extension immediately following medical intervention, but this is quite often not the case. Patients very commonly have a stiff wrist in neutral or slight flexion from immobilization, and the orthosis must be serially adjusted from the position of comfort into a position of wrist extension.

Weaning the patient from orthotic use is paramount as patients can become dependent on their splints for stability instead of building up wrist strength. Patients should be educated to the expected timeline for splint wear very early in their care. Communication with the physician and the patient with regards to an established timeline will help reduce dependence on static orthotic use by the patient. A good rule of thumb for weaning from static orthosis use is about 2-3 weeks following removal of casting or external fixation.

Static progressive resting hand orthoses can also be used later in treatment if extrinsic flexor tightness becomes an issue. The patient should be placed in a resting hand orthosis in a comfortable extended position with a very light stretch. Over a period of several weeks, the therapist can modify the orthosis to provide increased wrist extension and/or finger extension as needed. Make sure to educate the patient that “more stretch is not better.” The goal of static progressive splinting is to stretch the tissues as they are healing, allowing increased collagen production. Too much stretch can cause tissue tearing, pain, and deformation.



Amy's note: Patients who are especially averse to removal of their static orthosis will often agree to static progressive splinting as opposed to no support at all. This is interesting as static progressive splinting is actually putting a force on the wrist (most commonly to regain wrist extension) that is more aggressive than no orthotic use at all.

Education

Adaptive Equipment: Adapting tools to decrease stress on the hands is a basic strategy that most therapists were taught in school. Built-up handles, easy closing/opening devices for clothing, food packages, key holders, and electric tools are some basic ideas for adapting an environment and are much more readily available than they once were. Even large discount retailers offers built-up food prepping tools such as large-handled potato peelers and large-handled knives.



NorthCoast medical company has an entire magazine dedicated to adaptive equipment needs for cooking, self-care, and recreational activities such as reading and playing cards. NorthCoast will send a therapist those magazines for free upon request, and they also have the same magazine available online: go to www.ncmedical.com, and on the home page in the bottom left hand corner you will see a button to order catalogs for free, or shop the catalog online. Alternatively, a simple search on the computer for “adaptive equipment for the hand” will reveal many products and solutions that patients (and therapists) might never have thought of.

Fall Prevention: Although it may seem obvious to assess the risk of fall in a patient who presents with an injury from a fall, this often goes unnoticed, as many patients will justify the fall by mentioning a throw rug, a family pet, or a missed stair. However, the therapist would be prudent to assess the patient’s balance through further investigation by asking the patient if they have had more than one fall in the last three months and if they have a fear of falling. Medications can also be a factor in causing dizziness, so a thorough history is warranted as well. If the patient is found to be a fall risk through these questions or due to medication, the therapist should administer functional balance screens such as the Berg Balance Scale or complete the STEADI toolkit which includes the Timed Up and Go (or TUG), the 30 second chair stand, and the 4 stage balance test (cdc.gov/steady). Gait speed is also considered a reliable measure of fall risk. If the therapist is not familiar with these tests, the patient should be referred to a physical therapist for assessment of balance and gait speed as part of their comprehensive rehab program.

Complications

Sometimes, in spite of all that the physician, therapist, and patient can do, patients will have complications from distal radius fracture. Some of the more common serious complications are nerve compression, tendon involvement, associated carpal fractures, wrist instability, and chronic pain.

Nerve Compression

Median Nerve Compression: The most common comorbidity alongside a DRF is compression of the median nerve, or carpal tunnel syndrome. Whether caused by the actual injury itself, prolonged casting in a position of wrist flexion, or from chronic swelling to the carpal tunnel due to slow healing, the median nerve can become compressed, or it can develop adhesions to the surrounding tissue, resulting in numbness and tingling, weakness, and dropping items. It is the responsibility of the therapist to watch for symptoms of nerve compression throughout the course of treatment.

Median nerve compression is so common with DRF, that many surgeons will prophylactically release the carpal tunnel during an open reduction to fix the

fracture. Check your surgeon’s operative report for this information, as you will want to address the patient as a postoperative carpal tunnel release as well as an ORIF patient: patients should also have scar management and desensitization added to their home programs. If the patient has not had a release of the flexor retinaculum, it is wise to evaluate and continually monitor for symptoms of nerve compression throughout the course of treatment using common provocative testing used for carpal tunnel syndrome such as a positive Tinel’s test, Berger’s test, Phalen’s test, and/or Durkin’s test. Reviewing median nerve gliding exercises and performing them during treatment can also help alleviate slight cases of nerve irritation.

Positive provocative testing for median nerve compression should be reported immediately to the physician, who may wish to start the patient on an anti-inflammatory regimen (Keith, M. W. et al., 2010). Modify your patient’s treatment regimen to include more neutral wrist positioning as able, splinting at night or during aggravating activities, soft tissue mobilization to the thenar and hypothenar eminences, median nerve gliding exercises, tendon gliding exercises, a decompression series to stretch the flexor retinaculum, and modalities to reduce swelling as needed.

The American Academy of Orthopedic Surgeons recommends a custom static orthosis to increase patient comfort under circumstances of median nerve compression (AAOS, 2016). A custom orthosis provides better wrist support, positioning, and constant allocation of pressure over the carpal tunnel compared to pre-fabricated orthoses (Nucholls et al., 2011). The wrist should be placed in a neutral position during immobilization if nerve compression is suspected or confirmed. Research is not consistent with regards to a wearing protocol for carpal tunnel syndrome, and varies by provider. Some recommend wearing at night (Ono, Chapham & Chung, 2010), while others suggest wearing at night and during activity (Hall, Lee, Fitzgerald, Byrne, Barton, & Lee 2013).

Another modification to consider is blocking the MP joints into extension if the patient isn’t gaining relief with use of a traditional wrist cock-up splint to alleviate symptoms. This is in response to newer research that suggest that most people have migration of the proximal end of the lumbrical muscles into their carpal tunnel when they make more than a 75% fist (which naturally occurs while sleeping). Even with the wrist in neutral, if the lumbricals are impeding on the space in the carpal tunnel, this can cause a flare-up of neurological symptoms (Baker, Moehlingm, Rubinstein, Wollstein, Gustafsonk & Baratz, 2012).

Provocative testing should be performed at least every couple of weeks during the course of treatment to ensure that the patient isn’t developing any median nerve adhesions or compression, and the therapist should listen for complaints suggesting the same, such as increased pain at night, tingling or numbness during any activities

(or at rest), or point tenderness/irritation in the carpal tunnel with weight bearing. Early recognition of these symptoms can improve patient outcomes and comfort during their rehabilitation.

Dorsal Radial Sensory Branch Compression: The dorsal radial sensory nerve (DRSN) can also become irritated with casting due to post-injury swelling and tight immobilization. Patients will complain of numbness, tingling, and/or pain to the thumb, the dorsal web space, and the radial aspect of the index finger with compression of the DRSN. Treatment for DRSN compression is modifying the patient's positioning, radial nerve gliding, and desensitization techniques. The therapist can also provide soft tissue mobilization to the extensor wad (where the radial nerve bifurcates into the DRSN), which can reduce any proximal gliding and compression issues.

Tendon Involvement

Extensor Pollicis Longus Rupture and Tendinitis: Another fairly common complication following distal radius fracture is rupture of the extensor pollicis longus (EPL) tendon as it passes around the Lister's tubercle and changes direction. This happens in between 3-6% of DRF, most often with minimally displaced or nondisplaced distal radius fractures. Although the occurrence of rupture of the EPL in "simpler" DRF more than in complicated fractures sounds counterintuitive, this occurs because the extensor retinaculum typically is intact in a non-displaced fracture, so it causes the tendon to be held tight against the floor of the tunnel, which further causes the tendon to rub against the fracture site or internal fixation (Helal, Chen, Iwegbu, 1982). Attritional rupture can happen for a variety of reasons, but excessive dorsal callus formation, positional errors in screw placement during volar plate fixation, prominent osteotomy resection edges, and osteophytes are the leading contributors of attritional rupture of the EPL (Rivlin et al, 2012). Surgeons can often avoid this complication by performing a debridement of the dorsal surface of the area including the callus and Lister's tubercle.

Attritional rupture (rupture caused by bony formation or sharp edges) happens most often between 1-2 months post-operatively. Rupture due to technical errors such as improper screw placement tends to happen within the first six weeks (Roth et al., 2012). Patients may have some warning of this complication, complaining of pain or irritation with movement of the IP joint of the thumb; however, since tendons do not have nerve supply, patients may also have no warning whatsoever that their EPL is being damaged until the tendon ruptures and the patient no longer has active extension at the IP joint of the thumb.

If your patient is complaining of pain or difficulty with thumb motion, specifically located at the dorsal wrist around the second or third dorsal compartment (base of the second metacarpal), notify the physician of these findings and limit your patient's thumb IP motion until the area is evaluated by the hand surgeon. Your patient

may have tendonitis of the EPL from the tightened third dorsal compartment tunnel caused by callous formation, or may be damaging the tendon with risk of rupture. If your patient is found to have either of these conditions, typically the surgeon will release the third dorsal compartment which will remedy the symptoms and usually prevents EPL rupture – the tendon has space to move away from the bony floor and Lister's tubercle, which relieves the pressure on a swollen or irritated tendon.

After an EPL rupture, simple tendon repair is not usually possible due to the "shredding" of the tendon during movement. Therefore, the course of action is either a palmaris longus graft, or tendon transfer of the extensor indicis proprius to regain active use of the thumb. Both of these surgeries are time consuming with regards to rehabilitation, but yield satisfactory functional results (Skoff, 2003). Rehabilitation techniques after tendon repair or grafting are beyond the scope of this course.

Extensor Carpi Ulnaris Tendinopathy: Another site of tendinopathy (or damage to the tendon) after distal radius fracture is to the extensor carpi ulnaris (ECU) as it crosses over the distal ulna and inserts into the base of the fifth metacarpal. The ECU has a fibro-osseous sheath that ties into the TFCC, which helps stabilize it as it extends the ulnar aspect of the wrist. If the sheath is damaged, or there is damage to the TFCC which in turn causes instability of the ECU, the ECU will have more movement and friction over the distal ulna. This can cause pain, or very infrequently, rupture. If a patient complains of pain at the base of the fifth metacarpal on the dorsal aspect of the wrist, tendinitis of the ECU should be expected and activities should be modified to allow the tissue time to heal.

Flexor Tendon Rupture: Flexor tendon rupture is considered a major complication following volar plate fixation, and unfortunately it remains the most common complication seen with this surgery (Imatani & Akita, 2017). As described with the EPL, flexor tendon rupture can be caused by tendons rubbing against a bony fragment not appreciated on x-ray, or from rubbing against an ill-placed screw or the edge of a volar locking plate, or even being trapped under an ill-fitting locking plate. The placement of the volar locking plate proximal to the "watershed" line and early removal of the plate can reduce the risk of flexor tendon rupture (Asadollahi, 2013). Surgical complications can also be remedied by removing the screw or replacing the volar locking plate with one that is sized appropriately if the fracture site can tolerate the removal of hardware.

As with the EPL, oftentimes the ruptured flexor tendon will be difficult to repair due to the shredding effect of rubbing against a screw or bony fragment. Regardless of whether the tendon can be repaired normally, or grafting of the tendon with a palmaris longus graft or neighboring flexor tendon is necessary, a flexor tendon repair will require a major modification in the treatment of the distal radius fracture itself. Rehabilitation of a flexor tendon

repair is difficult in the face of an unhealed fracture, and will complicate the protocol, as wrist flexion will need to be maintained in order to allow tendon healing. It will most likely result in extreme wrist stiffness.

Amy's note: Tendons do not have their own nerve supply, which is a blessing and a curse in the case of tendon rupture. Because they do not have sensation on the actual tendon itself, a patient might not be aware that the tendon is being damaged, or that it is rubbing on any noxious surface. The first symptom of tendon damage can be the rupture itself. Essentially, a sudden change in finger motion, whether active or passive, should immediately be reported to the treating physician.

Associated Carpal Bone Fractures: Carpal bone fractures can often occur in conjunction with distal radius fracture, and are difficult to identify on diagnostic scans. They occur when the mechanism of injury involves a fall on a hyperextended wrist. The major complicating factor of adding a carpal fracture to a DRF is that carpal bones have notoriously poor blood supply and are susceptible to avascular necrosis. If a patient has a concurrent carpal bone fracture, the immobilization timeline may be greatly increased, sometimes up to 24 weeks as seen with proximal pole scaphoid fractures (Dell, 2011). Immobilization will often include the thumb if the fracture occurs on the radial aspect of the wrist, which will alter the amount of stiffness noted in the thumb following cast removal.

Complications often seen with carpal bone fractures (most often the scaphoid) are compression of the dorsal radial sensory nerve due to casting, avascular necrosis (as mentioned above), and scaphoid non-union advanced collapse (SNAC) wrist. SNAC wrist describes a scaphoid that does not heal correctly, causing an uneven surface on the proximal edge of the scaphoid where it articulates with the radius, and further causing articular breakdown and eventual arthritis. Patients complain of pain and swelling to the radial wrist, and usually have some loss of extension.

Carpal bone fractures complicate therapy programs in that they delay functional AROM activities and strengthening timelines when compared to simple distal radius fractures. The treatment is primarily the same, but will need to be adjusted for healing. Carpal bone fractures can also have associated ligament damage, which further complicates the healing and potentially the surgical outcomes.

Wrist Instability and Chronic Pain: The fourth complication seen with distal radius fracture is associated ligamentous damage, which can eventually lead to chronic carpal instability and pain. Damage to this complicated ligament system can lead to bony sheering, causing further impaction fractures, cartilaginous breakdown, and generalized wrist instability. This presents as chronic swelling, pain, and difficulty with gripping and weight bearing. Less severe complications can be noted insufficiency in the proprioceptive and kinesthetic sense

of the wrist, leading to “clumsy” hand function.

Physicians who suspect carpal instability can use provocative testing in the office or a diagnostic MRI or arthrogram to diagnose ligamentous disruption or strain. Depending on the damage found, arthroscopy to clean out frayed ligaments or surgical fixation may be necessary. The frustrating consequence of wrist instability is that it slows the progression of therapy, as patients cannot tolerate certain motions, strength training, or weight bearing. This makes it difficult to return to work and pre-injury activities.

The intercalated segment (or proximal row) is susceptible to instability after a fall on an outstretched hand, as the ligaments between the functional carpals can become strained or disrupted with injury. The most common instabilities are volar intercalated segmental instability (VISI) and dorsal intercalated segmental instability (DISI).

VISI is also referred to as palmar flexion instability, describing the abnormal volar tilt (more than 15 degrees) of the lunate compared to the scaphoid and triquetrum. This is an indication of a disruption of the lunotriquetral ligament. Incidentally, this can also be seen as a normal variant for people with lax ligaments, so comparison to the unaffected wrist is necessary. DISI, also called dorsiflexion instability, is an abnormal dorsal tilt (more than ten degrees) of the lunate, and subsequent abnormal volar tilt of the scaphoid. This can indicate a disruption of the scapholunate ligament. Any dislocation of the lunate (volar or dorsal) during injury can be an enormous complication for the patient with a distal radius fracture, because if ligamentous support is lost at the scapholunate or lunotriquetral joints, the wrist is at great risk of carpal collapse. Carpal collapse can eventually lead to unresolved pain, more motion, poor function, and arthritis.

DISI is the more common mid-carpal instability. A normal S-L angle is 30-60 degrees, and the S-L angle of someone with DISI is greater than 70 degrees. Once the relative angle reaches 70 degrees, the ligaments are not functional to perform pain free motion. DISI is most commonly seen with scaphoid fractures and peri-lunate dislocations, which can be a complication after a fall on an outstretched hand. If you suspect that your patient has carpal instability and do not feel comfortable performing provocative testing, please contact the physician so that he may address your concerns. If DISI is found to be present, therapy will need to be modified to avoid end-range wrist motions, and the patient will be a surgical candidate. Carpal arthrodesis is the recommended surgical choice if the ligament cannot be salvaged.

Amy's note: Unfortunately, wrist instability can also be caused by aggressive therapy practices. Since the job of the ligaments is to provide stability to the joint, that stability can be compromised by aggressive stretching, joint mobilizations, exercises, or weight bearing if the ligaments are damaged in any way. If a patient has tightness in the actual DRUJ, the patient can compensate by overstretching the ulnar carpal ligaments, which will make it appear that the patient has more

supination than they really do. This will cause the patient to have less stability and strength in the long run. In order to avoid this complication, make sure to support the ulnar carpus during forearm stretching, dynamic splinting to regain motion, and joint mobilizations with either orthotics or manual support.

As noted previously, ligamentous disruption or damage can compromise the patient's proprioceptive sense. Proprioception is made up of three components: kinesthetic sense, joint position sense, and neuromuscular reeducation (Hagert, 2010). Kinesthetic sense is the ability to sense the motion of the joint; the angle of position is the joint position sense; and neuromuscular reeducation is the ability of the muscles to move dynamically and synergistically to maintain balances motion of the joint. After distal radius fracture, patients can often have ligament insufficiency or even chronic swelling that affects the function of the ligaments, causing proprioceptive decline in the wrist: the patient cannot sense the speed of motion or degree of positioning in the wrist.

This can be monitored and evaluated by the therapist as the protocol allows by occluding the patient's vision and passively placing the affected wrist into some degree of flexion or extension and having the patient mimic that sensation on the unaffected wrist. Conversely, the therapist could place the unaffected wrist in a position and have the patient try to mimic this motion with the affected wrist (again, with vision occluded). If the patient has a measurable difference in placement of the two wrists, the therapist should include proprioceptive training in their clinic and home program.

Proprioceptive rehab activities include bilateral weight bearing over a ball, isometric exercises in various joint positions, eccentric and concentric strengthening, and use of items such as a Dynaflex Powerball, Gyroscope, or Hand Maze to work through various wrist motion patterns.



Other techniques that have previously only been used for neurological dysfunction are now being found to be beneficial for orthopedic injuries as well. Patients who are immobilized for long period of time can begin to have laterality problems (discriminating right from left), which is very subtle. Graded motor imagery (GMI) can be employed for patients who are presenting with long-term motor pattern issues and proprioceptive deficiency. A GMI

program involves three stages of rehab, beginning with laterality training, progressing to visualization, and concluding with mirror therapy.

Ulnar Sided Wrist Pain: Most patients will report ulnar sided wrist pain with motion and activity following a distal radius fracture. Although this can be indicative of ligament damage, it can also be due to soft tissue irritation from the injury. Swelling to the ulnar snuff box and tenderness with palpation is common, and should be noted in the therapist's evaluation. If the pain persists after 8-12 weeks of treatment, it should be discussed with the surgeon. Knowing the provocative motions and activities performed that cause pain will help the surgeon order the appropriate diagnostic imaging or decide to move to wrist arthroscopy. For example, reporting that the patient has ulnar sided wrist pain with resisted pronation can assist the surgeon in focusing his search for soft tissue damage of the TFCC. Ulnar sided wrist pain with weight bearing can indicate ligament damage. With regards to treatment, document your findings and then avoid provocative positions, motions, exercises, and activities until symptoms subside or the patient is cleared by the surgeon.

Surgical Procedures following Complications

Further surgical intervention to reduce pain, improve movement, and improve function of the hand may be necessary. Following are some of the more common procedures that can be seen after complications from distal radius fracture.

Suave-Kapandji Procedure: The Suave-Kapandji procedure is indicated for patients that have distal radial ulnar joint arthritis with pain and limited motion. This can be caused by primary arthritis, or secondary arthritis due to a distal radius fracture or ulna fracture. This surgery involves resection of the distal end of the ulna and fusion of the intact ulnar head to the radius. This procedure can only be performed in patients that have a normal to negative ulnar variance (as opposed to some of the other procedures mentioned here). The Suave-Kapandji procedure helps reduce pain and maintains functional forearm rotation.

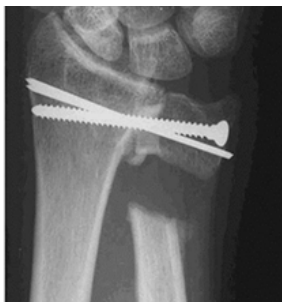Carpal Fusions: When a patient has advanced collapse of the wrist due osteoarthritic changes in the distal radius, and tears to the scapholunate ligament and TFCC, the surgeon may recommend a carpal fusion or proximal row carpectomy to reduce pain and maintain as much motion as possible. A four corner fusion (4CF), three corner fusion (3CF), and proximal row carpectomy (PRC) are all viable surgical options to reduce pain and improve use of the SNAC and SLAC wrists. The joint surfaces of the radius and all three bones (and associated joints) of the proximal row are assessed to determine which procedure is most appropriate. The scaphoid is often excised, as it is the carpal that moves the most with wrist motion, so it interferes with positive results of a fusion. Bone graft from the excised scaphoid can be used as part of the fusion, and various fixation techniques are employed such as screws, staples, k-wires, and plates (Bain, 2012).

Patients are immobilized after any fusion surgery for a period of about 6-8 weeks, and then may begin light AROM activities. Strengthening is rarely initiated prior to about 12 weeks when fusion has been confirmed through diagnostics. Patients may or may not be undergoing therapy during the interim for scar management, edema management, and to avoid soft tissue adhesions to the digits. Full healing after wrist fusion occurs between 12-24 months post-operatively (Bain, 2012).

Volar Capsular Release and Volar Locking Plate Removal: In patients with residual wrist extension stiffness following distal radius fracture, one surgical intervention is to perform a subperiosteal volar capsule release, tenolysis of the flexor carpi radialis tendon, and removal of the volar locking plate. Although some surgeons are concerned that this will lead to carpal instability and volar subluxation, research suggests that outcomes are quite good, favoring increased wrist motions including wrist extension, pronation and supination, and patient-related functional improvements as noted on the DASH. Radiocarpal and ulnocarpal relationships were unchanged as noted through diagnostic testing, making this a seemingly effective intervention choice for severe ROM limitations (Kamal, 2017).

Patients that have undergone this procedure will typically be referred back to therapy for increased range of motion and strengthening. There is not a universally accepted protocol for the rehab following this procedure, so communication with the surgeon will be necessary in order to clarify any restrictions for active and passive motion and strengthening.

Ulnar Shortening Osteotomy: Patients who continue to have ulnar-sided wrist pain and limited range of motion (specifically ulnar deviation) may have healed with a positive ulnar variance due to the shortening of the length of the radius from the fracture, causing ulnar impaction syndrome. This variance leads to degenerative changes due to the overload between the ulna and its carpal articulations. The ulna is designed to bear 20% of the weight bearing load, and if the ulna has a positive variance, this can cause degenerative tears in the TFCC, tears in the triquetrolunate ligament, and ulnocarpal osteoarthritis. Ulnar shortening osteotomy (USO) surgically shortens the ulna to relieve the excess stress. There are several options for USO, including intra-articular and extra-articular options, and further varying from open to arthroscopic procedures. The advantage of the USO is that the DRUJ and TFCC remain intact.



Patients who undergo an ulnar shortening osteotomy are generally immobilized in a long arm splint for about 4 weeks, and a short arm splint for 4-12 weeks depending on the status of the healing osteotomy. After a wafer resection (the least invasive osteotomy procedure: a 2-4mm wafer of the distal ulna is removed, as opposed to a full osteotomy), the patient is immobilized for about 3 weeks, and begins careful AROM after that, returning to fairly normal use of the hand in about 6-8 weeks. All ulnar shortening osteotomy rehabilitation should be careful of weight bearing activities for 8-12 weeks to allow for bone healing. Eccentric ECU strengthening and isometric strengthening should be employed to regain pain-free use of the hand in functional activities.

VI. Case Studies

Case Study #1

A.C. was a 16-year old healthy high school junior who was an active basketball player and state-qualifying triple jumper for her high school team.

She suffered a fall during a high school basketball game, but did not note anything more than a slight wrist pain during the fall, and kept playing the game. Over the next couple of weeks, A.C. developed some wrist swelling, and started to note some mild wrist pain. She was seen by her primary care physician who ordered x-rays that were negative. She was told she had a wrist sprain and was instructed to rest as needed to reduce pain, but was not restricted from any activities by her physician. She finished out her basketball season with mild complaints of wrist pain that she was able to “play through.”

Four months later, A.C. was shutting the trunk of her car when she felt a non-painful “pop” in her wrist and noticed that her index finger “wasn’t working.” Being a 17-year old, she didn’t mention it to anyone, and says she “kind of forgot about it.” About one month later, A.C. had another finger “pop” and stop working. Her mother took her back to her primary physician who stated that she was compensating for the wrist sprain (and pain she was still experiencing), and she was instructed to try to use her hand as normally as possible. She had some mild swelling, and mild pain, but her primary complaint was that her fingers wouldn’t move.

Over a period of several more months, A.C. eventually lost all function of her PIP and DIP joints of the right (dominant) hand. She was able to actively flex her MP joints, but was unable to make a hook fist, or use her hand for most functional activities. She was seen by her local hand surgeons and the consensus was that since her series of x-rays over those several months were negative, her injury was psychosomatic. The recommendation was for her to see a psychiatrist.

A.C. sought a second opinion from a hand surgeon an hour from her home. The physician agreed that A.C.

needed a specialist, and referred her to a hand surgeon in New York City. When that surgeon opened up A.C.'s wrist for exploratory surgery, he found a small bone chip from her distal radius that had dislodged, flipped around, and embedded itself on the interosseous membrane of her distal forearm. (In defense of all her previous physicians, he rechecked the x-rays and was unable to find the bone chip on x-ray.)

Unfortunately, by the time A.C. was seen by the diagnosing physician, the rough side of the bone chip had shredded all eight of the flexor tendons that ran through her carpal tunnel, leaving her without any motion to her index, middle, ring, and small fingers at either the PIP or DIP joints. She was able to actively flex her MP joints because they are controlled by intrinsic muscles that do not run through the carpal tunnel. This injury had never been documented in the medical community.

The fracture was not of consequence, as the small bone chip was covered in callus and the chipped end of the distal radius was well-healed. However, the patient had no functional use of her right hand, which was devastating. The proximal end of the flexor tendons had retracted into the forearm and the distal ends of the tendons basically reabsorbed into the body. A flexor tendon repair was impossible as there was not enough tendon tissue to insert into the joints. The physician placed Hunter silastic rods (spacers) in the carpal tunnel at the time of the first surgery, and identified as many of A.C.'s eight flexor tendons as he could find in the forearm, pulled them to as much length as he could, and tied them down to the distal end of the forearm in order to keep them from reabsorbing as well. This surgery happened almost a year after the initial injury.

A.C. started occupational therapy after her first surgery in order to maintain the PROM of her finger joints, address soft tissue restrictions in her flexor wad from the tendons retracting into her forearm, to address the fact that the muscle tissue was atrophied from lack of use, and to manage the 22 cm incision she had from the distal palmar crease to half way up her volar forearm.

Six months later, A.C. underwent her second surgery with the OT present for observation, which was the most complicated of the six surgeries she would eventually have for this injury. In this surgery, the physician used flexor tendon grafts taken from the left wrist (palmaris longus), and the right leg (plantaris longus) to recreate four flexor tendons to the DIP joints of each finger. The surgeon did not think he had room to attempt to repair all eight due to bulk of the repairs as well as to avoid tendon adhesions.

A.C. started OT immediately upon returning home, 3-5 days per week for the next 15 months until the patient left for college, when she was transferred to another facility and decreased her frequency to 2-3 days per week. The patient continued to transfer back and forth between two therapists depending on if she was at school or on break. She was also a college athlete, so her

therapy schedule was compromised by classes, practice, and track meets. Therapy during all of this time involved a quadruple flexor tendon grafting protocol, including scar management, AROM, PROM, edema control, muscle reeducation, and eventual strengthening.

Over a period of two more years, the patient underwent tenolysis every six months, for a total of six surgeries. She wore at least six different types of orthoses, had a home program for four years, and underwent multiple painful surgeries to regain function of her hand. She is now married, has four children under the age of seven, and is a teacher at the local high school. She has adequate functional use of her hand, but continues to have extrinsic flexor tightness in her wrist that bothers her from time to time. (This case study was used with permission by the actual patient.)

Amy's note: I'm sharing this case study to demonstrate that the simplest of distal radius fractures turned into a multi-year, multi-surgery fiasco due to soft tissue injury. This could give a therapist nightmares for months.

Case Study #2

J.M. was a 35-year old male who worked as an ironworker. He had no significant medical history, no surgical history to the upper extremities, and no systemic underlying disease to report.

He sustained a Colles fracture to the left (non-dominant) wrist when he fell 13 feet from some scaffolding at work due to safety equipment failure. J.M. was not a surgical candidate, and was placed in a standard Colles cast (slight wrist flexion) for eight weeks.

The cast was removed at 8 weeks when fracture healing had been achieved, and J.M. was referred to therapy to regain his range of motion and strength to return to work. He had severe stiffness to the wrist (about 15 degrees of total active flexion/extension) and his MP joints were extremely stiff. He was able to actively flex his MP joints to about 20 degrees, and 30 degrees passively. J.M. did not complain of significant pain, had minimal to no noted edema, and was extremely compliant with therapy.

Traditional hand therapy was implemented: AROM of the wrist and fingers, fluidotherapy for desensitization and to increase blood flow, and initiation of joint mobilizations and PROM about 2 weeks after AROM began. J.M. made slight improvement the first 3 weeks of therapy, but around week 3.5-4, he began having increased swelling and stiffness after his treatment sessions. J.M. denied any significant pain with his therapy program, he was able to demonstrate his exercises appropriately, and was not suspect for malingering. He simply responded to each therapy session with increased swelling and stiffness, which seemed to be worsening with each successive treatment session.

Although this did not follow the "normal" course of CRPS (as there were absolutely no complaints of pain),

J.M. was exhibiting an interesting pattern of exacerbated symptoms that seemed to coincide with his manual therapy. He had no pain, but his body responded to manual treatment by flaring up his swelling and stiffness. After four weeks of therapy, he had virtually no wrist motion in flexion/extension, or radial/ulnar deviation. His MP joints were “frozen” in a neutral position. He could not bear weight over the wrist at all because he couldn’t place his hand in a position of wrist extension to bear weight. He was actually more stiff than he was when he came out of the cast.

Therapy for this patient was completely modified to remove ALL passive modalities from his program. We removed fluidotherapy, PROM, joint mobilizations, and traditional tendon glides and wrist AROM exercises. We also limited AAROM (active assistive range of motion) exercises as well. We compiled a list of functional activities for him to complete on his own timeline while attending therapy. He sorted various textures, manipulated nuts and bolts, played with theraputty, playing cards, checkers, and other fine motor items. He performed weight bearing over a small ball as tolerated, and worked on push-pull using a light sled. J.M came to therapy for about 90 minutes per session, and was completely independent (mimicking a work hardening type patient). His only instructions were to vary his activities and keep track on his clipboard of what he completed, and if he had any increase in swelling, stiffness, or pain with treatment or after treatment. Within three therapy sessions, J.M.’s exacerbated symptoms began to subside.

J.M. continued with this type of program for six weeks, and activities progressed per his tolerance as time when on. Six weeks after we began the treatment designed for patients with CRPS, J.M. had full ROM of his wrist and all of his digits with no chronic pain, swelling, or side effects. He was able to return to his job as an ironworker at 15 weeks post injury with 80% of his grip strength compared to the unaffected side.

J.M. sustained a fairly “simple” fracture, but had a sudden onset of complication that didn’t follow a normal pattern of injury. By adjusting his treatment protocol to respect how his body was responding to treatment, he was able to achieve all of his goals and return to his career.

Conclusion

The rehabilitation of distal radius fractures can be frustrating at times, as there are so many factors to consider. The severity of the fracture itself, the complications associated with the accident, the previous medical history, as well as the compliance and expectations of the patient are all contributors in the patient’s eventual outcome. Evidence-based research and functional outcome screens continue to provide therapists with the guidelines and motivation we need to provide the best practice we have available to us. As science and

technology continue to advance, we will certainly find new and better ways to treat these patients medically and therapeutically. Keep moving forward!

Additional Resources

DASH and QuickDASH information
<http://www.dash.iwh.on.ca>

Functional outcome screens, can be used freely online
www.orthopaedicscores.com

MMDT, Purdue Pegboard
www.lafayetteinstruments.com

Protocols, classification systems, interesting hand links
www.eatonhand.com

References

- Asadollahi, S, Prue, K. (2013). Flexor tendon injuries following plate fixation of distal radius fractures: a systematic review of the literature. *J Orthop Traumatol Dec*; 14(4): 227–234.
- Bain GI, McGuire DT, (2012). Decision making for partial carpal fusions. *J Wrist Surg*. 2012 Nov; 1(2): 103–114.
- Baker NA, Moehling KK, Rubenstein EN, et al., 2012. The comparative effectiveness of combined lumbrical muscle splints and stretches on symptoms and function in carpal tunnel syndrome. *Arch Phys Med Rehabil* 93:1-10.
- Brehme, JL, Husband, JB. (2014). Accelerated rehabilitation compared with a standard protocol after distal radial fractures treated with volar open reduction and internal fixation: a prospective, randomized, controlled study. *J Bone Joint Surg Am*. Oct 1;96(19):1621-30.
- Bringer TL, Rogers JC, Holm MB, Baker NA, Li ZM, Goitz RJ (2007). Efficacy of fabricated customized splint and tendon and nerve gliding exercises for the treatment of carpal tunnel syndrome: A randomized controlled trial. *American Congress of Rehabilitation Medicine*, 88, 1429-1436.. Re-Printed in Coppard & Lohman, (2015)
- Brogren E, Petranek M, Atroshi I. (2007). Incidence and characteristics of distal radius fractures in a southern Swedish region. *BMC Musculoskelet Disord*. 8:48
- Christersson A, Larsson S, Sandén B. (2017). Clinical outcome after plaster cast fixation for 10 days versus 1 month in reduced distal radius fractures: A prospective randomized study. *Scand J Surg*. Sep 1:1457496917731184. doi: 10.1177/1457496917731184. [Epub ahead of print]
- Chung KC, Spilson SV. (2001).The frequency and epidemiology of hand and forearm fractures in the United States. *J Hand Surg Am*. 26:908–915.
- Coppard, B.M., & Lohman, H. (4th. Ed.) (2015). Introduction to orthotics: A clinical reasoning and problem-solving approach. St Louis: Mosby.

- Cooper, C. (2014). *Fundamentals of hand therapy: Clinical reasoning and intervention guidelines for common diagnoses of the upper extremity* (2nd Ed). St. Louis: Mosby.
- Crisco JJ, Coburn JJ, Moore DC, et al. (2005). In vivo radiocarpal kinematics and the dart thrower's motion, *J Bone Joint Surg Am.* 87: 2729-2740.
- Davis DI, Baratz M. (2010). Soft tissue complications of distal radius fractures, *Hand Clin* 26(2): 229-235.
- de Putter CE, van Beeck EF, Looman CW, Toet H, Hovius SE, Selles RW. (2011). Trends in wrist fractures in children and adolescents, 1997–2009. *J Hand Surg Am.*;36:1810–1815. e2.
- Dell P, Dell R, Griggs R: Management of carpal fractures and dislocation. In Skirven T, Osterman AI, Fedorczyk J, et al: *Rehabilitation of the hand and upper extremity*, ed 6, Philadelphia, 2011, Elsevier.
- Evans, R. (2011). Therapist's management of carpal tunnel syndrome: A practical approach. In T.M. Skiven, A.L.Osterman, J.M. Fedorczyk, & P.C. Amadio (Eds). (2011). *Rehabilitation of the hand and upper extremity*. (6th ed,) Philadelphia: Elsevier Mosby.
- Faulkner RA, Davison KS, Bailey DA, Mirwald RL, Baxter-Jones AD. (2006). Size-corrected BMD decreases during peak linear growth: implications for fracture incidence during adolescence. *J Bone Miner Res.* 21:1864–1870.
- Hagert E. (2010). Proprioception of the wrist joint; a review of current concepts and possible implications on the rehabilitations of the wrist. *J Hand Ther* 23(1):2-16.
- Hall, B., Lee, H.C, Fitzgerald, H., Byrne, B., Barton, A., & Lee, A.H. (2013). Investigating the effectiveness of full-time wrist splinting and education in the treatment of carpal tunnel syndrome: A randomized controlled trial. *American Journal of Occupational Therapy*, 67, 4, 448-459.
- Handoll H., Elliott J. (2015). Rehabilitation for distal radial fractures in adults. *Cochrane Database Syst Rev.* Sep 25;(9):CD003324.
- Helal B, Chen SC, Iwegbu G. (1982). Rupture of the extensor pollicis longus tendon in undisplaced Colles' type of fracture. *Hand.* 1982 Feb;14(1):41-7.
- Hudak PL, Amadio PC, Bombardier C. Development of an upper extremity outcome measure: the DASH (disabilities of the arm, shoulder and hand) [corrected]. The Upper Extremity Collaborative Group (UECG). *Am J Ind Med.* 1996 Jun;29(6):602-8.
- Jebsen RH et al. (1969). An Objective and Standardized Test of. Hand Function, *Arch Phys Med Rehabil*, 50 (6): 311-318.
- Kamal RN, Ruch DS. (2017) Volar Capsular Release After Distal Radius Fractures. *J Hand Surg Am.* Sep 14. pii: S0363-5023(17)31414-4. doi: 10.1016/j.jhsa.2017.08.002. [Epub ahead of print]
- Keith, M. W. et al. (2010). Clinical practice guideline on the treatment of carpal tunnel syndrome. *Journal of Bone and Joint Surgery*, 92, 218-219.
- Lipman MD, Hess DE, Werner BC, Deal DN. (2017). Fibromyalgia as a Predictor of Complex Regional Pain Syndrome After Distal Radius Fracture. *Hand.* Oct 1:1558944717735949. doi: 10.1177/1558944717735949. [Epub ahead of print]
- Mackin EJ, Callahan AD, editors: *Hand clinics: frontiers in hand rehab*, Philadelphia, 1991, WB Saunders.
- MacDermid JC, Turgeon T, Richards RS, Beadle M, Roth JH. Patient rating of wrist pain and disability: a reliable and valid measurement tool. *J Orthop Trauma.* 1998 Nov-Dec;12(8):577-86.
- Maheshwari J. *Essential Orthopaedics*. Jaypee Brothers Medical Pub. (2012) ISBN:8184655428.
- Martinez-Mendez D, Lizaur-Utrilla A, de-Juan-Herrero J. (2017). Intra-articular distal radius fractures in elderly: a randomized prospective study of casting versus volar plating. *J Hand Surg Eur Vol.* Jan 1:1753193417727139.
- Mathison DJ, Agrawal D. (2010). An update on the epidemiology of pediatric fractures. *Pediatr Emerg Care*; 26:594–603.
- McClure P (2003). Evidence-based practice: An example related to the use of splinting in a patient with carpal tunnel syndrome. *Journal of Hand Therapy* 16(3):256-263.
- Medoff R, (2011). Distal radius fractures: classification and management. In Skirven T, Osterman AL, Fedorczyk J, et al: *Rehabilitation of the hand and upper extremity*, ed 6, Philadelphia, Elsevier, pp 941-948.
- Michlovitz, S.L., LaStayo, P.C. Alzner, S., Watson, E. (2001). Distal radius fractures: Therapy practice patterns. *Journal of Hand Therapy*, 249-257.
- Munk PL, Munk P, Ryan A. (2007). *Teaching Atlas of Musculoskeletal Imaging*. Thieme Medical Pub. ISBN:1588903729.
- Nellans K, Kowalski E, Chung K. (2012). The Epidemiology of Distal Radius Fractures. *Hand Clin.* May; 28(2): 113–125.
- Nuckols, T., Harber, P., Sandin, K., Benner, D, Weng, H., Shaw, R., Griffin, A., Asch, S. (2011). Quality measures for the diagnosis and non-operative management of carpal tunnel syndrome in occupational settings. *Journal of Occupational Rehabilitation*, 21, 100-119.
- Ono, S., Clapham, P. J., Chung, K. C. (2010). Optimal management of carpal tunnel syndrome. *International Journal of General Medicine*, 3, 255-261.
- Orbay JL, Touhami A. (2006). Current concepts in volar fixed-angle fixation of unstable distal radius fractures. *Clin Orthop Relat Res.* Apr; 445(0):58-67.

Palmer AK, Werner FW, Murphy D, et al. (1985) Functional wrist motion; a biomechanical study, *J Hand Surg Am* 10:39-46.

Raittio L, Launonen A, Hevonkorpi T, Luokkala T, Kukkonen J, Reito A, Sumrein B, Laitinen M, Mattila VM. (2017). Comparison of volar-flexion, ulnar-deviation and functional position cast immobilization in the non-operative treatment of distal radius fracture in elderly patients: a pragmatic randomized controlled trial study protocol. *BMC Musculoskelet Disord.* 18: 401.

Rivlin M, Fernández DL, Nagy L, Graña GL, Jupiter J. (2012). Extensor pollicis longus ruptures following distal radius osteotomy through a volar approach. *Journal of Hand Surgery Am.*, 41(3), 395-8.

Roth KM1, Blazar PE, Earp BE, Han R, Leung A. (2012). Incidence of extensor pollicis longus tendon rupture after nondisplaced distal radius fractures. *Journal of Hand Surgery Am.* 2012 May; 37(5): 942-7.

Ryan LM, Teach SJ, Searcy K, et al. (2010). Epidemiology of pediatric forearm fractures in Washington, DC. *J Trauma.* 69:S200–S205.

Skoff HD. (2003). Postfracture extensor pollicis longus tenosynovitis and tendon rupture: a scientific study and personal series. *Am J Orthop.* May;32(5):245-7.

Smaby N, Johanson ME, Baker B, et al. (2004). Identification of key pinch forces required to complete functional tasks. *J Rehabil Res Dev* 41(2): 215-224.

Surrey, L., Nelson, K., Delelio, C., Mathie-Majors, D., Omel-Edwards, N., Shumaker, J., & Thurber, G. (2003). A comparison of performance outcomes between the Minnesota Rate of Manipulation Test and the Minnesota Manual Dexterity Test. *Work*, 20(2), 97-102.

Walenkamp MM, de Muinck Keizer RJ, Goslings JC, Vos LM, Rosenwasser MP, Schep NW. (2015). The Minimum Clinically Important Difference of the Patient-rated Wrist Evaluation Score for Patients With Distal Radius Fractures. *Clin Orthop Relat Res.* 2015 Oct;473(10):3235-41.

Wei DH, Poolman RW, Bhandari M, Wolfe VM, Rosenwasser MP. (2012). External fixation versus internal fixation for unstable distal radius fractures: a systematic review and meta-analysis of comparative clinical trials. *J Orthop Trauma.* 2012 Jul;26(7):386-94.

Zhang Y. (2012). *Clinical Epidemiology of Orthopedic Trauma.* Thieme. ISBN:3131660414.

IMAGES

Picture of splints reprinted with permission from Patterson Medical/ Sammons, Preston & Rolyan and Allied Medical

Pictures of orthoses from the Coppard & Lohman book printed with permission from Mosby and from Access Medical reprinted copyright free.

DISTAL RADIUS FRACTURES: REHABILITATIVE EVALUATION AND TREATMENT

(5 CE HOURS)
FINAL EXAM

- _____: Intra-articular fractures of the radial styloid process. These occur most commonly from a blow to the dorsal wrist. Typically reduced with closed reduction and percutaneous pinning or a lag screw.
 - Chauffer fracture
 - Galeazzi fracture
 - Greenstick fracture
 - Reverse Barton fracture
- _____: Fracture of the growth plate of children or teens. These are serious, as they can affect the child's growth, and need to be assessed by a hand surgeon.
 - Barton fracture
 - Colles fracture
 - Reverse Barton fracture
 - Salter-Harris fracture
- _____: Pattern of osteoarthritis and subluxation due to untreated chronic scapholunate dissociation or from chronic scaphoid non-union.
 - Complex Regional Pain Syndrome (CRPS)
 - Kienbock's disease
 - Scapholunate Advanced Collapse (SLAC)
 - Ulnar impaction syndrome
- _____: Test to rule out carpometacarpal phalangeal (CMC) joint osteoarthritis; the examiner provides an axial load to the first metacarpal on the trapezium, and performs a circular motion, assessing for joint instability and/or pain. The test is positive if the patient complains of pain or if joint instability or "slippage" is noted.
 - Bunnel-Littler test
 - Durkin's test
 - Grind test
 - Tinel's test
- _____: Test for median nerve compression; the patient places her hands in a "reverse" praying position, with shoulders abducted, and the dorsal surface of each hand touching. If the patient complains of numbness or tingling within 90 seconds, the test is marked as positive.
 - Berger's test
 - Bunnel-Littler test
 - Grind test
 - Phalen's test
- _____: Measures the amount of ulnar impaction present in the wrist. Perform a grip strength test in neutral, pronation, and supinated. The strength ratio of supination to pronation is calculated and compared to the contralateral side. A ratio of greater than one is indicative of ulnar impaction.
 - Gripping rotary impaction (GRIT) test
 - Lunotriquetral ballottement test
 - Watson's "catch up clunk"
 - Watson's test
- The _____ has always been considered part of the proximal row, but is actually a sesamoid bone that is the insertion point for the flexor carpi ulnaris tendon. It does not play a role in the functional mobility of the proximal carpal row.
 - Lunate (L) bone
 - Pisiform (P) bone
 - Scaphoid (S) bone
 - Triquetrum (Tq) bone
- The proximal row is also known as the "_____" and refers to the scaphoid, lunate and triquetrum as they move in relation to each other with wrist motion.
 - Articular component
 - Hinge
 - Intercalated segment
 - Stabilizer
- The dorsal intrinsic wrist ligaments are _____ the volar intrinsic ligaments.
 - Less well-defined, and not as strong as
 - Less well-defined, but stronger than
 - More well-defined, and not as strong as
 - More well-defined, and stronger than
- The _____ of the wrist is the most function-based description of true wrist motion in daily life. It is a multi-planar movement of radial extension and ulnar flexion.
 - Active flexion
 - Dart-throwing motion (DTM)
 - Radial deviation
 - Ulnar deviation

11. The _____ is the most commonly used classification system for fractures of the distal forearm. The system takes into account several factors that affect predicted outcomes such as the degree of dorsal angulation, the degree of impaction, the degree and direction of displacement, the location of the medial fracture line (in other words, does it involve the radioulnar joint), and the presence of intra-articular fractures such as ulnar styloid fracture.
- AO classification system
 - Eaton classification system
 - Fernandez classification system
 - Frykman classification system
12. Distal radius fractures are one of the most common types of fractures in the United States, accounting for _____ of all fractures in the emergency room.
- 15%
 - 25%
 - 30%
 - 40%
13. By the time a woman is in her nineties, she is _____ times more likely to have a distal forearm fracture than a man.
- 3
 - 5
 - 7
 - 9
14. The majority of distal radius fractures are treated with immobilization (casting) from the proximal forearm and extending distally to the metacarpal heads. The wrist is placed in slight flexion and ulnar deviation in the “_____” position in order to use the surrounding soft tissue to help maintain the fracture reduction.
- Barton cast
 - Chauffeur cast
 - Colles cast
 - Smith cast
15. The _____ is the gold standard treatment for open reduction and internal fixation of distal radius fractures and has been used more and more over the past decade.
- Dorsal Locking Plate (DLP)
 - Internal Fixative Pin (IFP)
 - Volar Locking Plate (VLP)
 - None of the above
16. Considering potentially complicating comorbidities to distal radius fracture, the presence of _____, an autoimmune disorder, indicates that increased healing will need to be factored in when deciding on a timeline of return to functional activity. PROM of joints is contraindicated.
- Fibromyalgia
 - Lymphedema
 - Osteoarthritis
 - Rheumatoid Arthritis
17. Which of the following is NOT a symptom of complex regional pain syndrome (CRPS)?
- Brawny edema
 - Dull, flaky skin
 - Increased vasomotor instability (blue or red skin color changes)
 - Unrelenting stiffness
18. The _____ is designed to measure the physical function and symptoms in people with UE musculoskeletal disorders. It consists of 30 activities that a patient self-rates their level of difficulty performing on a scale from 0% (no difficulty) to 100% (unable to perform).
- Disability of the Arm, Shoulder, and Hand (DASH) screen
 - Michigan Hand Outcomes Questionnaire (MHQ)
 - Patient Rated Evaluation for the wrist (PRE)
 - Rated Evaluation for the wrist/hand (PRWE)
19. In addition to the use of a ruler, thumb opposition can be measured using a _____.
- Bunnell-Littler test
 - Median nerve gliding series
 - Modified Kapandji Index
 - Volumeter
20. In assessing fine motor coordination, the _____ is a functional hand assessment that evaluates a patient's ability to perform common functional tasks after injury or surgery. The original version of the test was developed in 1969 and has seven activities, but a modified version was approved for use in 2004, using three activities.
- Jebson-Taylor Hand Function Test (JHFT)
 - Minnesota Manual Dexterity Test (MMDT)
 - Nine-hole peg test
 - Purdue pegboard

21. Active range of motion (AROM) of the wrist and “involved” joints of the injury should begin, gently, following immobilization (with permission from the surgeon). When setting priorities with the patient, it is MOST important to stress _____.
- Achieving a painful end range
 - Intentional movement
 - Number of exercise sessions per day
 - Number of repetitions
22. In addition to median nerve gliding treatment, _____ may also help alleviate median nerve irritation in patients with an onset of numbness during the rehabilitation phases for distal radius fractures.
- Lumbrical stretches
 - Passive range of motion exercises
 - Static progressive splinting
 - The “prayer stretch”
23. The most underrated complication following a distal radius fracture, _____ is the leading cause of poor outcomes, as it can “clog up” in the hand and create soft tissue adhesions. Controlling this condition is critical to treatment.
- Edema
 - Extrinsic flexor tightness
 - Extrinsic extensor tightness
 - Nerve irritation
24. Physical agent modalities have been a complement to hands on treatment for many decades, and can be used both to prepare tissue for manual treatment and to calm it after aggressive exercise. _____ can temporarily relieve pain in some patients, although typically joint pain doesn’t respond as readily as muscle tissue does.
- Cold laser
 - Continuous ultrasound
 - Diathermy
 - Electrical stimulation
25. In the author’s experience, increasing _____ seems to be one of the most important clinical factors that influence whether or not a patient feels s/he has made adequate progress with therapy.
- Grip strength
 - Pinch strength
 - Postural guarding
 - Range of motion
26. Orthotics are commonly used in the management of distal radius fractures for a variety of reasons. A good rule of thumb for weaning from static orthosis use is about _____ following removal of casting or external fixation.
- 36 hours
 - 5-8 days
 - 2-3 weeks
 - 6-9 weeks
27. Considering complications that arise from distal radius fracture, the most common co-morbidity alongside a DRF is _____.
- Dorsal radial sensory branch compression
 - Extensor carpi ulnaris tendinopathy
 - Flexor tendon rupture
 - Median nerve compression
28. _____ is considered a major complication following volar plate fixation, and remains the most common complication seen with this surgery.
- Extensor carpi ulnaris tendinopathy
 - Extensor pollicis longus rupture
 - Flexor tendon rupture
 - Volar intercalated segmental instability
29. Carpal bone fractures can often occur in conjunction with distal radius fracture. Which of the following is NOT a complication often seen with carpal bone fractures?
- Avascular necrosis
 - Compression of the dorsal radial sensory nerve (due to casting)
 - Extensor carpi ulnaris tendinopathy
 - Scaphoid non-union advanced collapse (SNAC) wrist
30. Following complications, further surgical intervention to reduce pain, improve movement, and improve function of the hand may be necessary. _____, a surgery involving resection of the distal end of the ulna and fusion of the intact ulnar head to the radius, is indicated for patients that have distal radial ulnar joint arthritis with pain and limited motion.
- A proximal row carpectomy (PRC)
 - A volar capsule release
 - An ulnar shortening osteotomy (USO)
 - The Suave-Kapandji procedure

ANSWER SHEET

First Name: _____ Last Name: _____ Date: _____

Address: _____ City: _____

State: _____ ZIP: _____ Country: _____

Phone: _____ Email: _____

License/certification # and issuing state/organization _____

Clinical Fellow: Supervisor name and license/certification # _____

Graduate Student: University name and expected graduation date _____

** See instructions on the cover page to submit your exams and pay for your course.

By submitting this final exam for grading, I hereby certify that I have spent the required time to study this course material and that I have personally completed each module/session of instruction.

Distal Radius Fractures: Rehabilitative Evaluation and Treatment Final Exam

- | | | | | |
|--------------------|---------------------|---------------------|---------------------|---------------------|
| 1. (A) (B) (C) (D) | 7. (A) (B) (C) (D) | 13. (A) (B) (C) (D) | 19. (A) (B) (C) (D) | 25. (A) (B) (C) (D) |
| 2. (A) (B) (C) (D) | 8. (A) (B) (C) (D) | 14. (A) (B) (C) (D) | 20. (A) (B) (C) (D) | 26. (A) (B) (C) (D) |
| 3. (A) (B) (C) (D) | 9. (A) (B) (C) (D) | 15. (A) (B) (C) (D) | 21. (A) (B) (C) (D) | 27. (A) (B) (C) (D) |
| 4. (A) (B) (C) (D) | 10. (A) (B) (C) (D) | 16. (A) (B) (C) (D) | 22. (A) (B) (C) (D) | 28. (A) (B) (C) (D) |
| 5. (A) (B) (C) (D) | 11. (A) (B) (C) (D) | 17. (A) (B) (C) (D) | 23. (A) (B) (C) (D) | 29. (A) (B) (C) (D) |
| 6. (A) (B) (C) (D) | 12. (A) (B) (C) (D) | 18. (A) (B) (C) (D) | 24. (A) (B) (C) (D) | 30. (A) (B) (C) (D) |

Accessibility and/or special needs concerns?
Contact customer service by phone at (888) 564-9098
or email at support@pdhacademy.com.

Refund and general policies are available online at
<http://pdhacademy.com/policies/>

DISTAL RADIUS FRACTURES: REHABILITATIVE EVALUATION AND TREATMENT

(5 CE HOURS)

COURSE EVALUATION

Learner Name: _____ Completion Date: _____

PT PTA OT OTA SLP SLPA Other: _____

	Disagree					Agree	
	1	2	3	4	5		
Orientation was thorough and clear	1	2	3	4	5		
Instructional personnel disclosures were readily available and clearly stated	1	2	3	4	5		
Learning objectives were clearly stated	1	2	3	4	5		
Completion requirements were clearly stated	1	2	3	4	5		
Content was well-organized	1	2	3	4	5		
Content was at or above entry-level knowledge	1	2	3	4	5		
Content was substantiated through use of references, footnotes, etc.	1	2	3	4	5		
Content reflected stated learning objectives	1	2	3	4	5		
Exam assessed stated learning objectives	1	2	3	4	5		
Exam was graded promptly	1	2	3	4	5		
Satisfied with learning experience	1	2	3	4	5		
Satisfied with customer service (if applicable)	1	2	3	4	5	n/a	

What suggestions do you have to improve this program, if any?

What educational needs do you currently have?

What other courses or topics are of interest to you?
